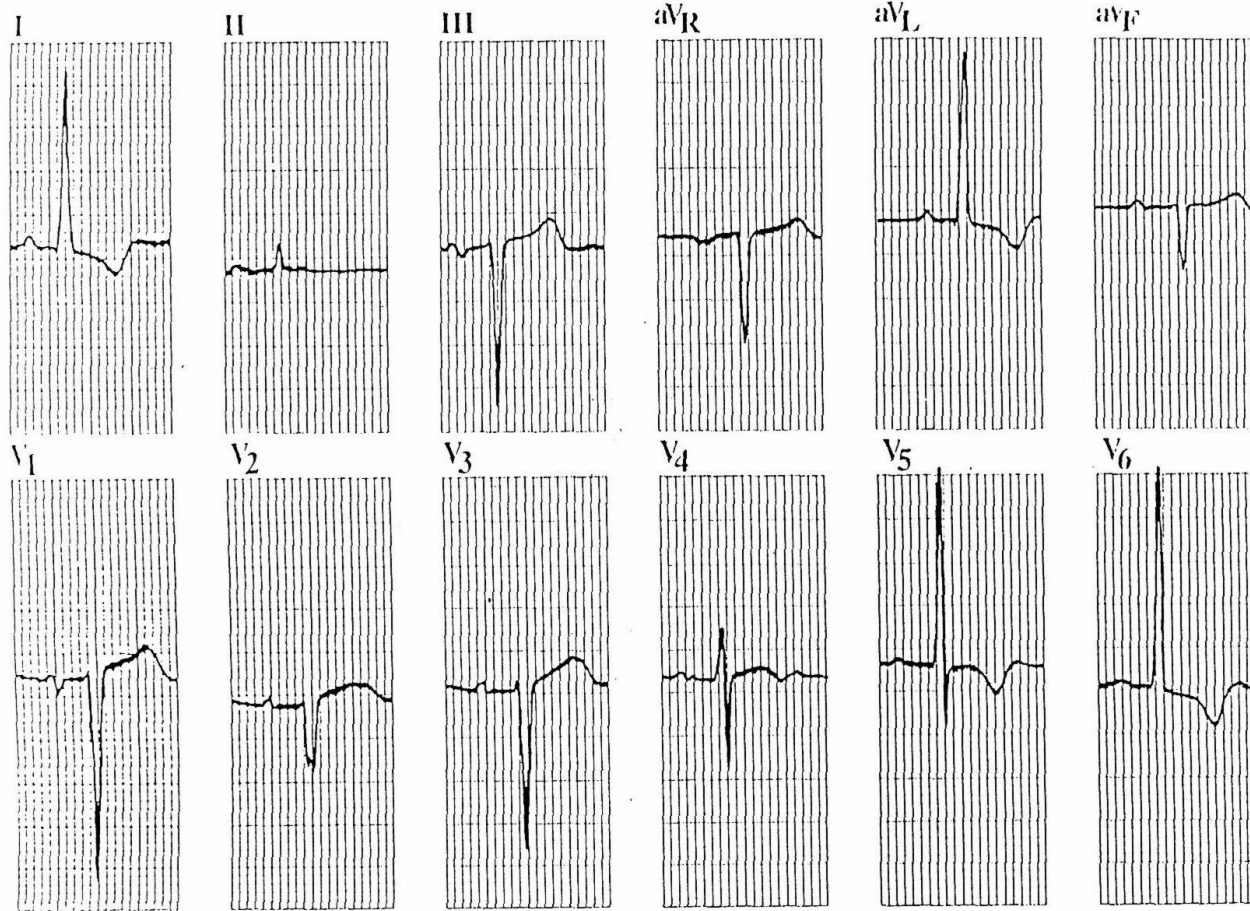
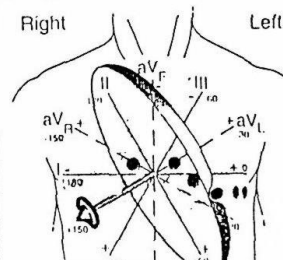
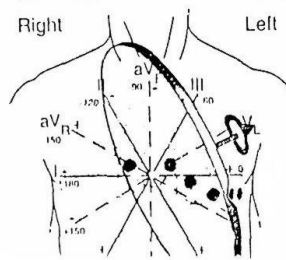


1.

Depolarization & Repolarization Vectors (Left Axis Deviation)

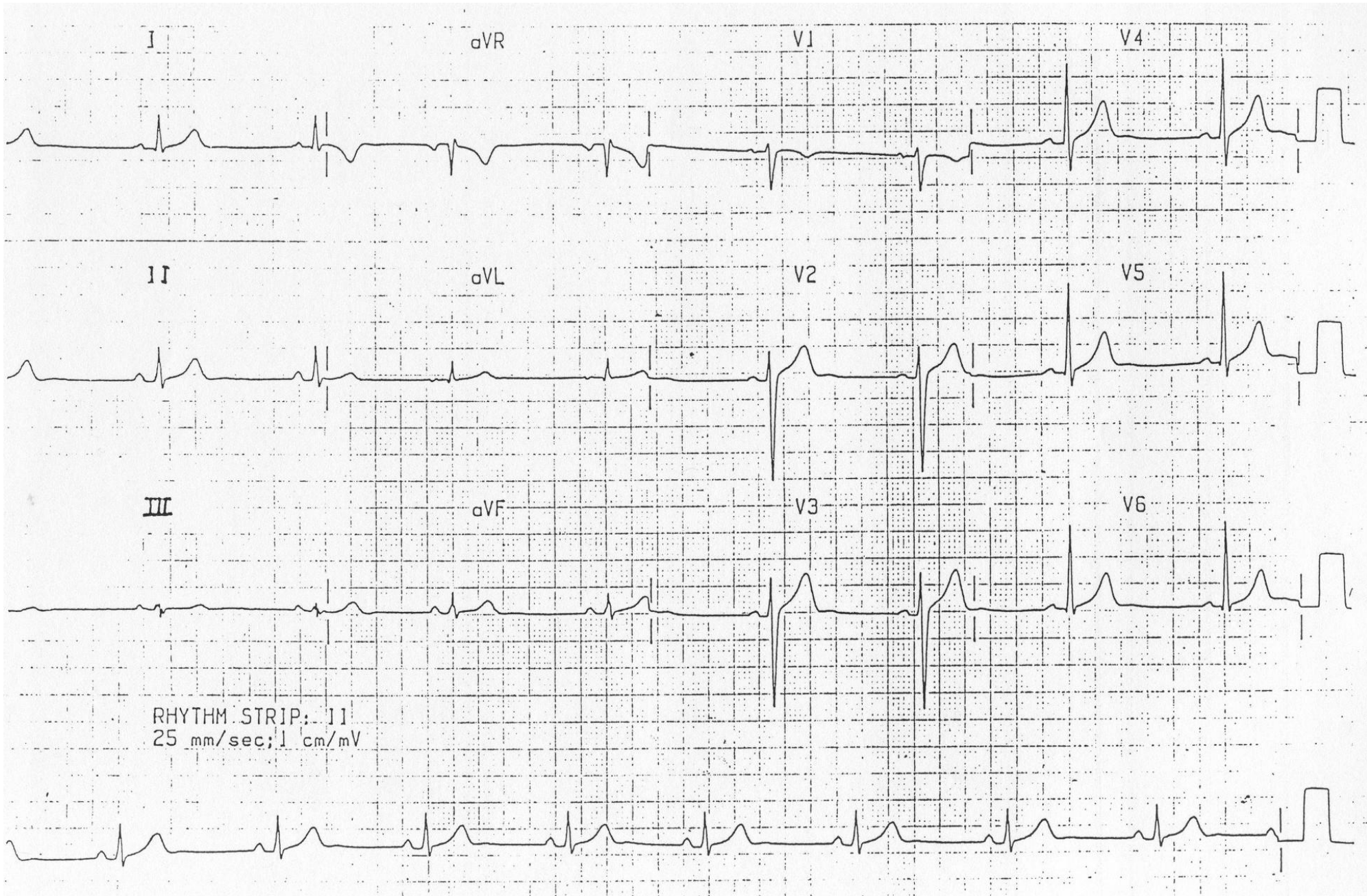


Depolarization Vector
(2 dimensional value is the "axis")

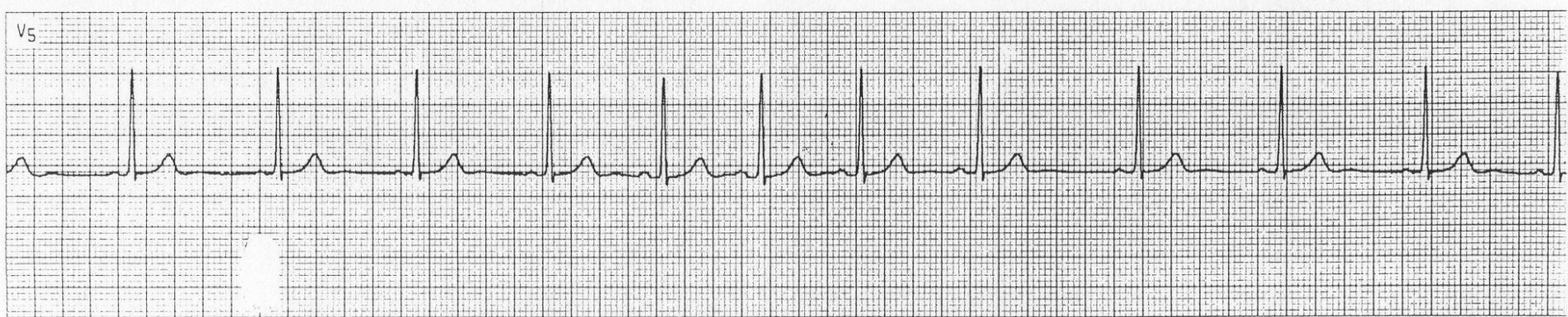
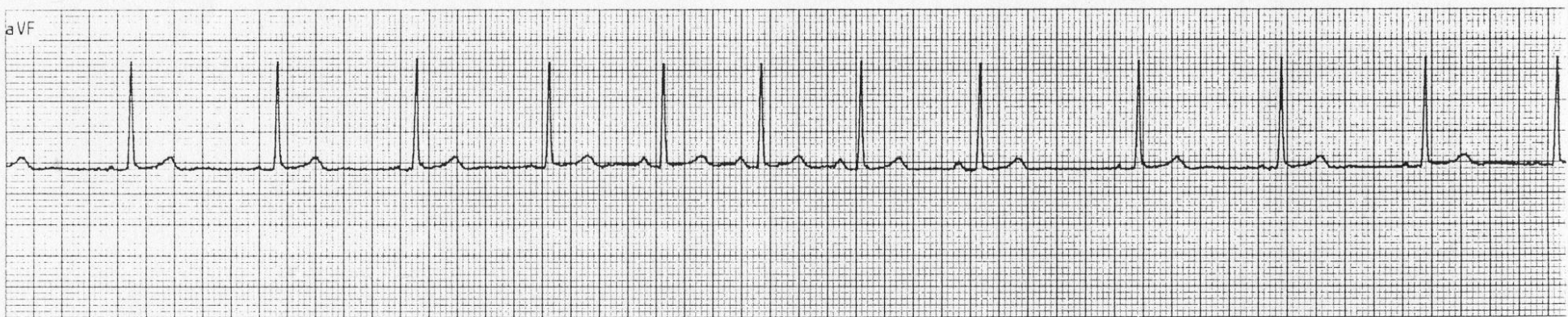
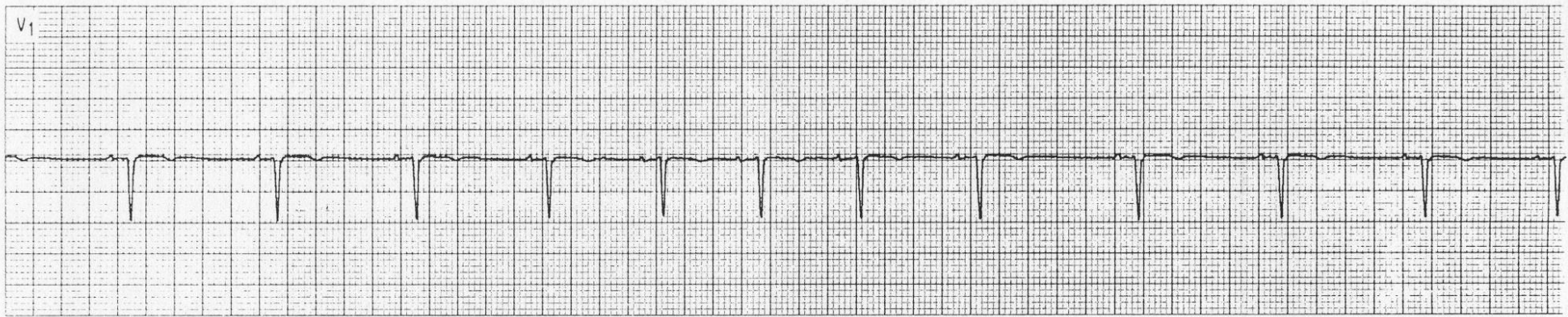


Repolarization Vector

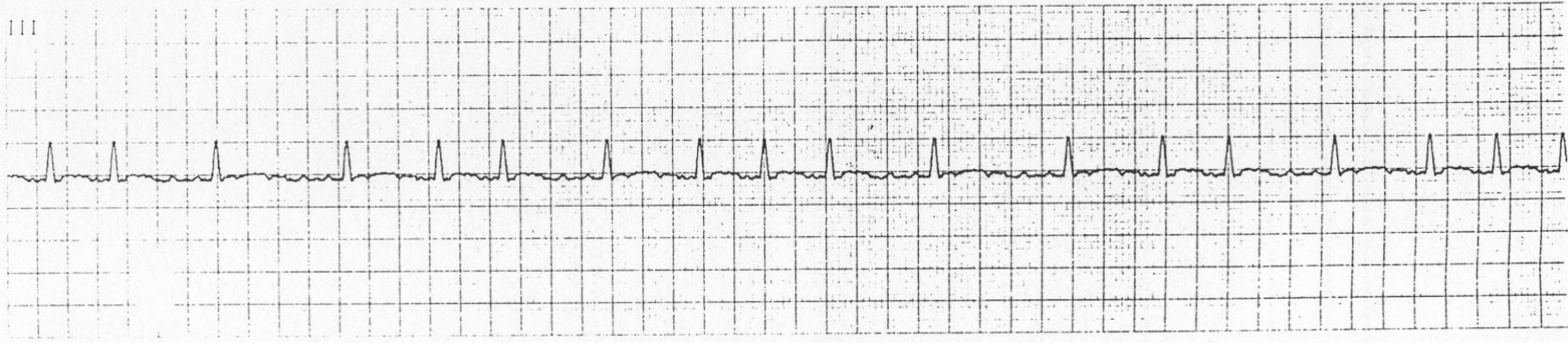
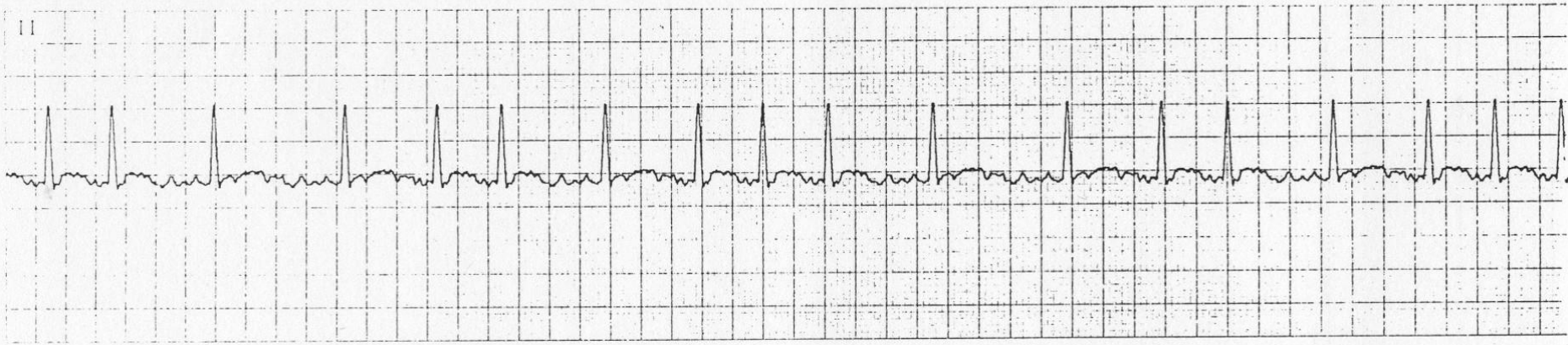
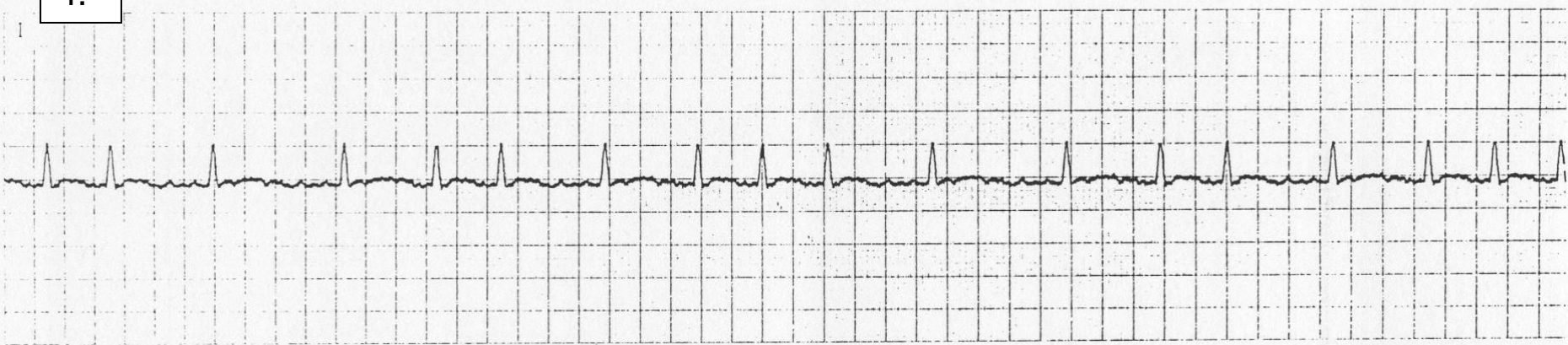
2.



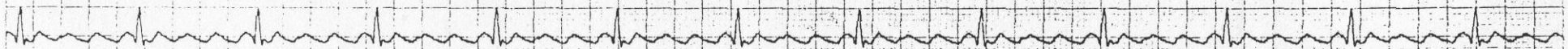
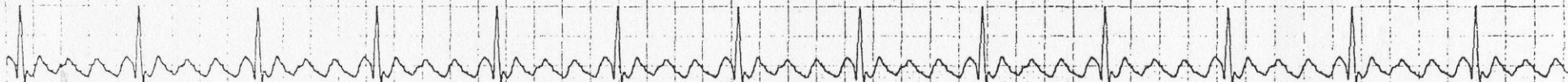3.



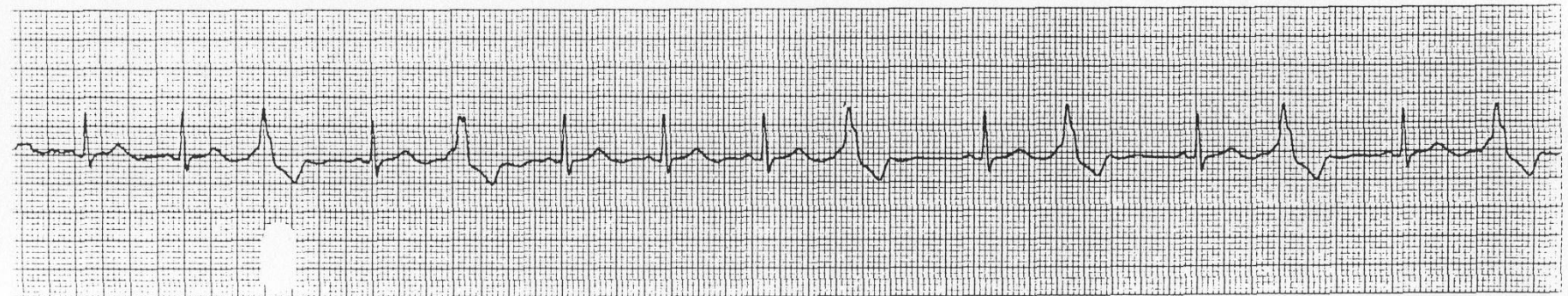
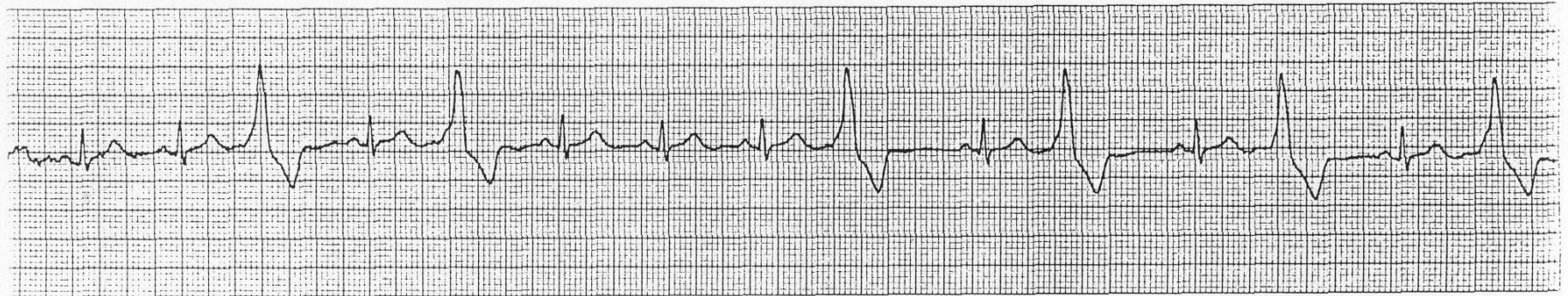
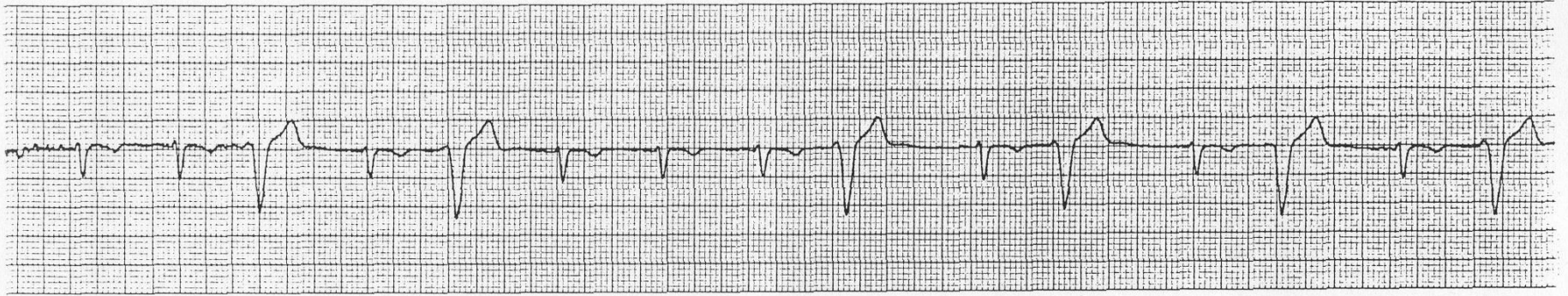
4.



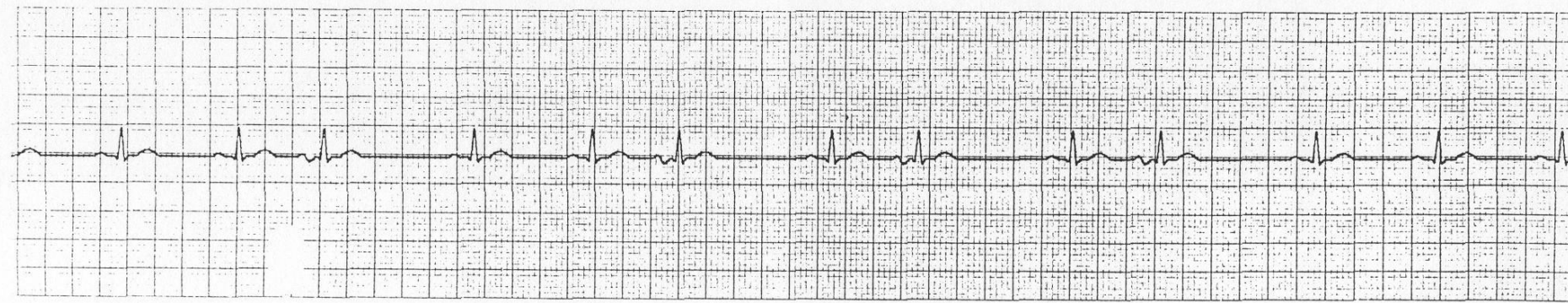
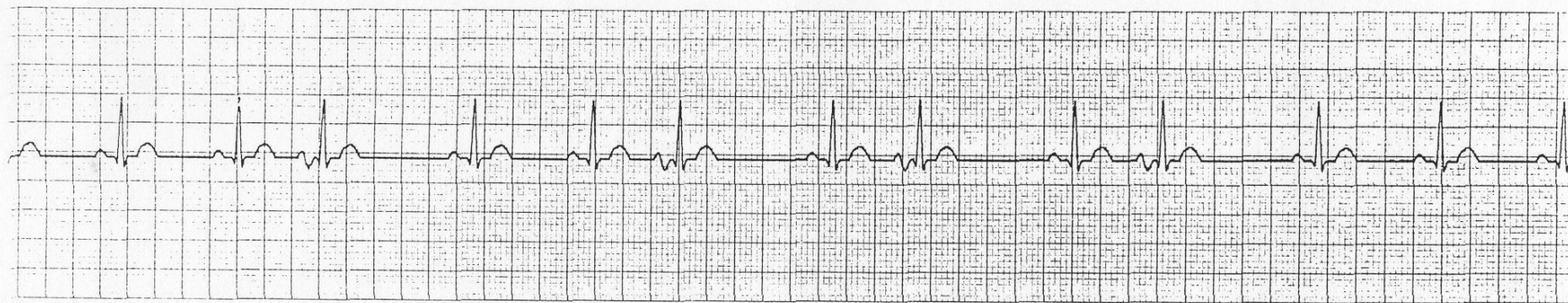
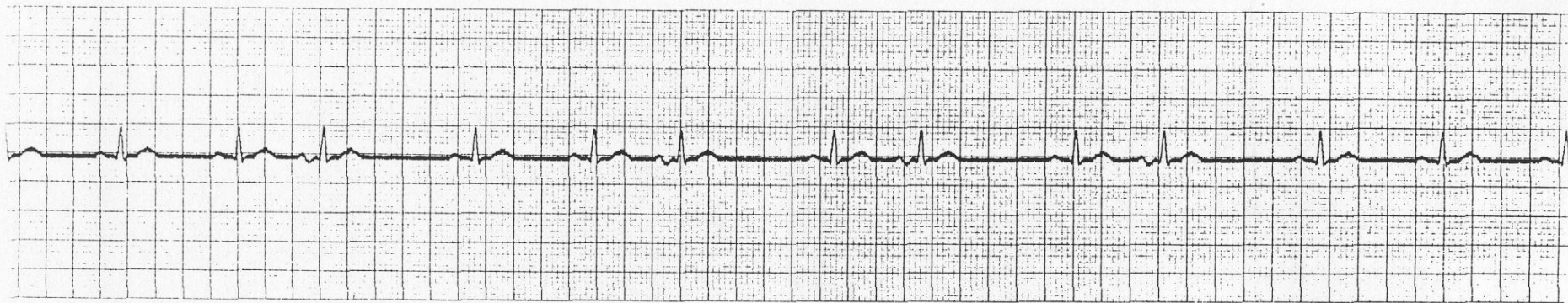
5.



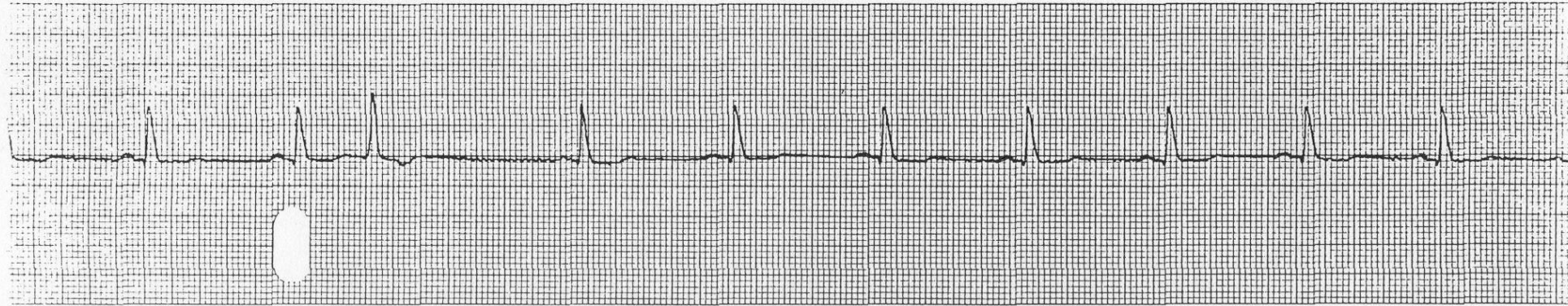
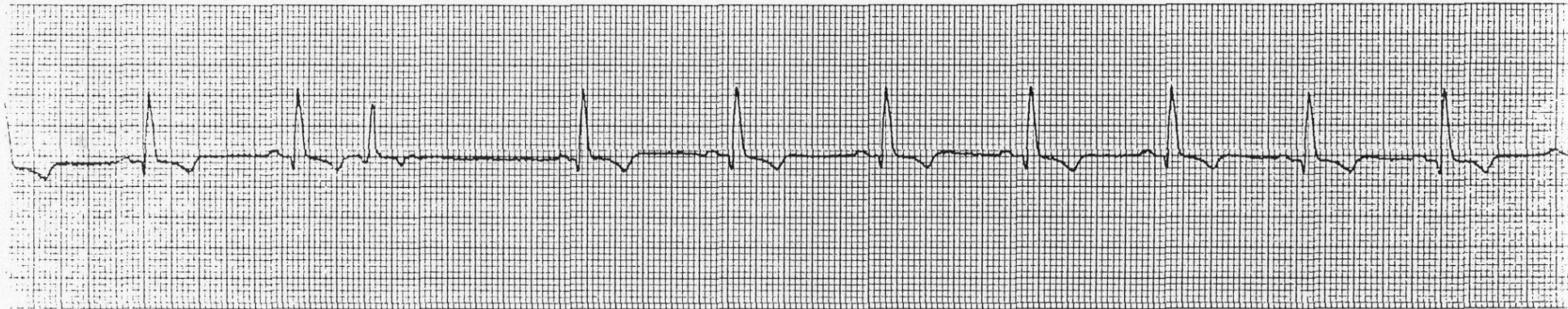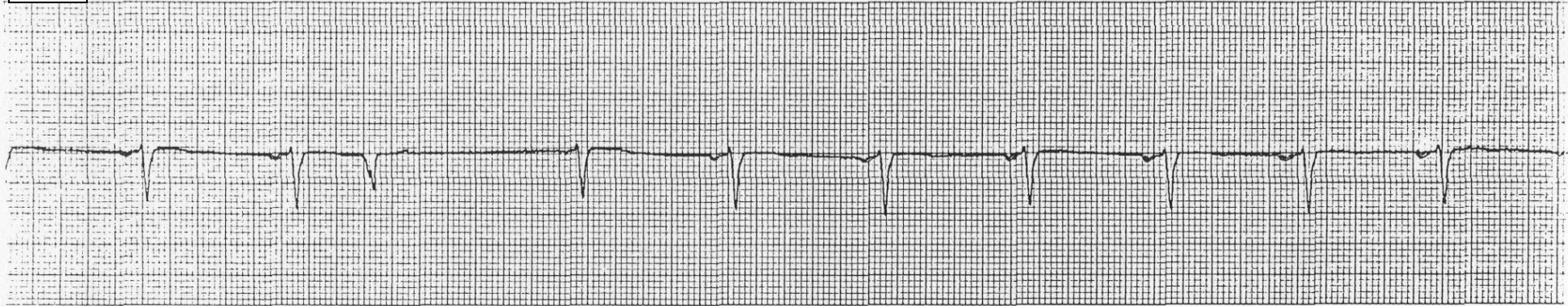
6.



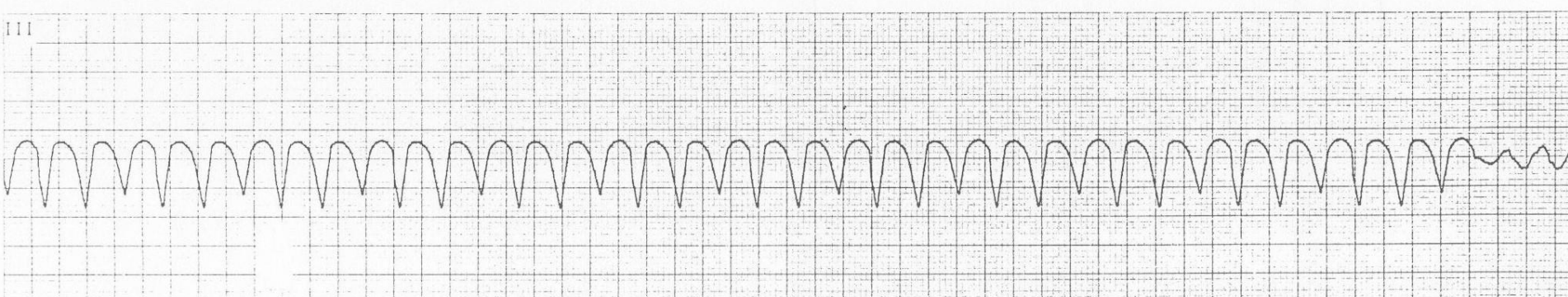
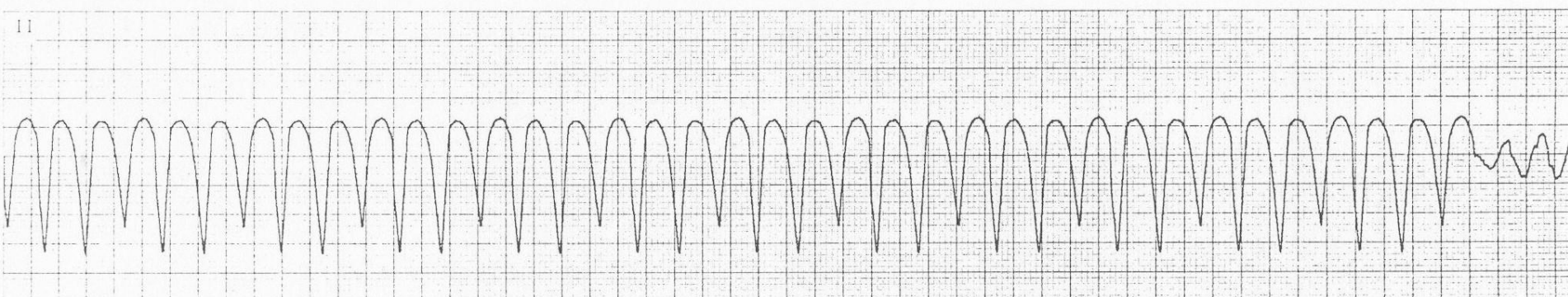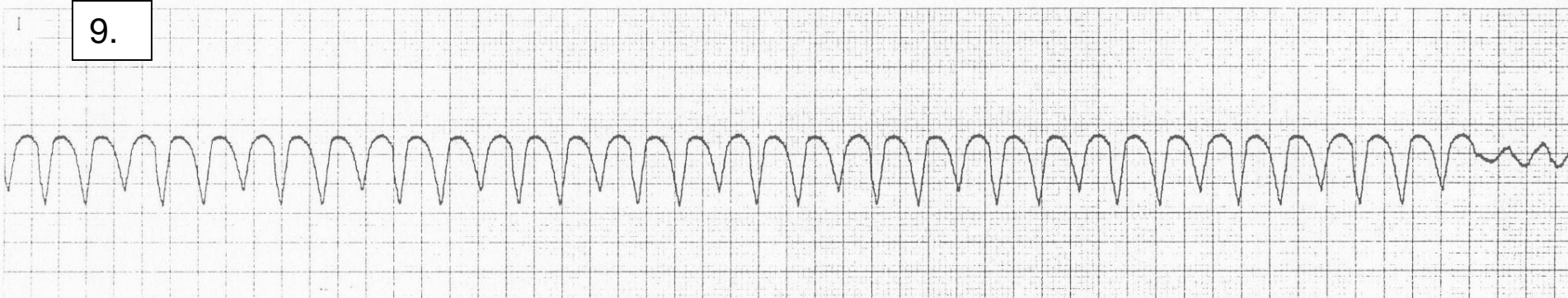
7.



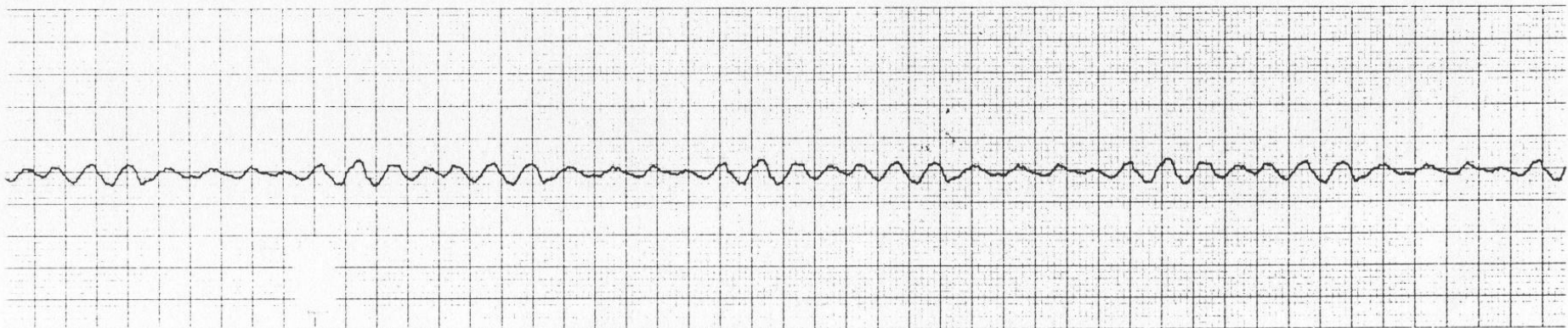
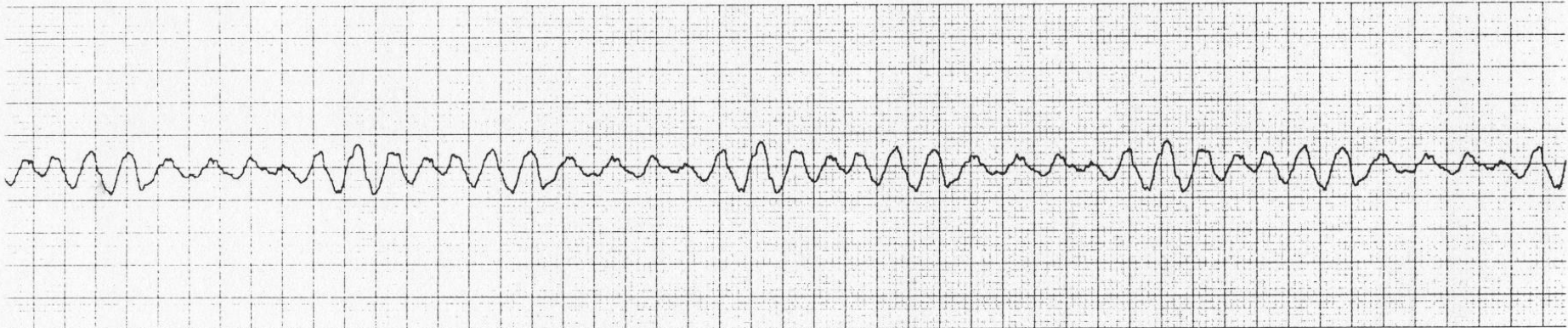
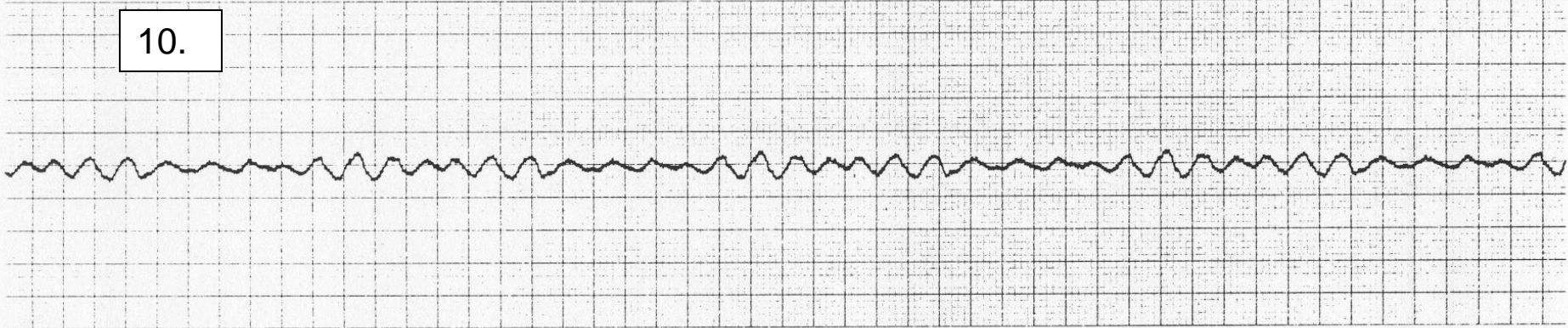
8.



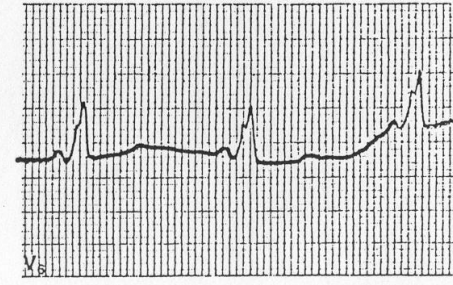
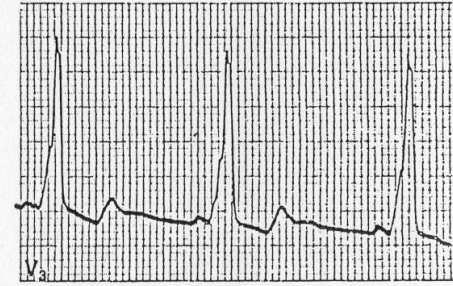
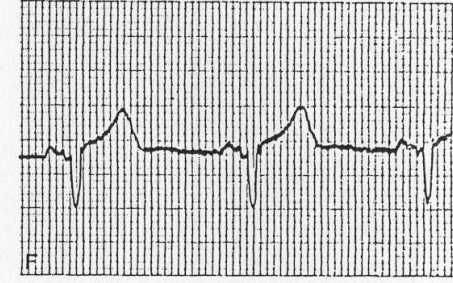
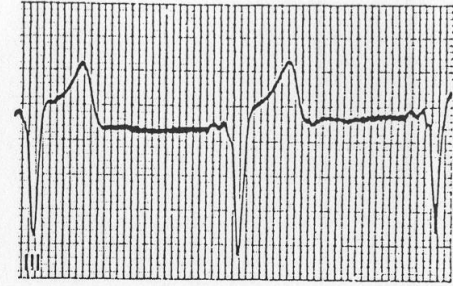
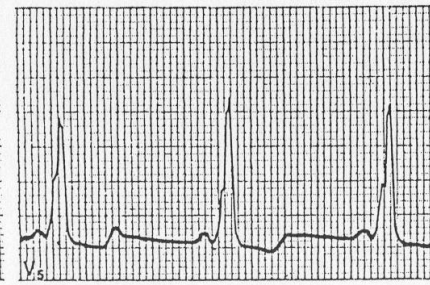
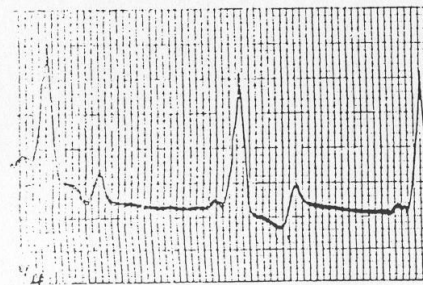
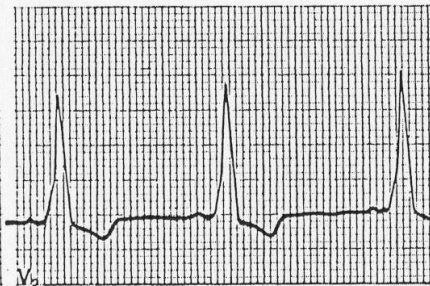
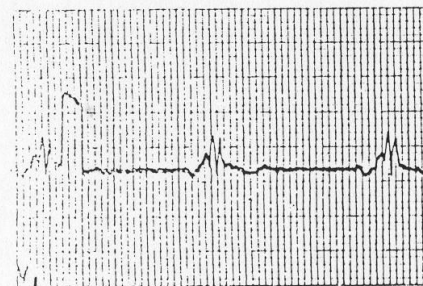
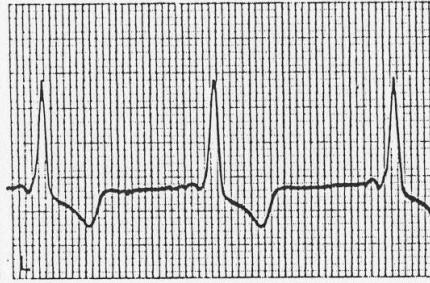
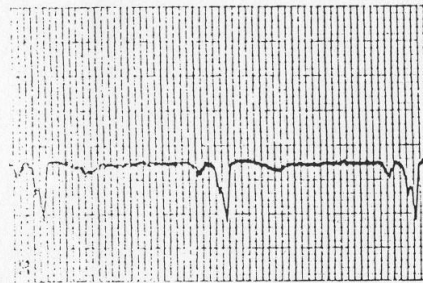
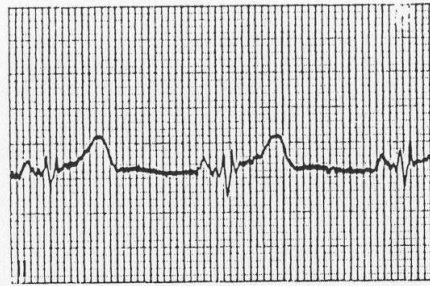
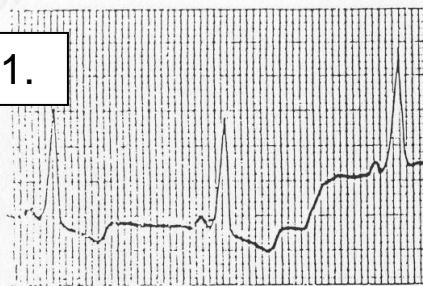
9.



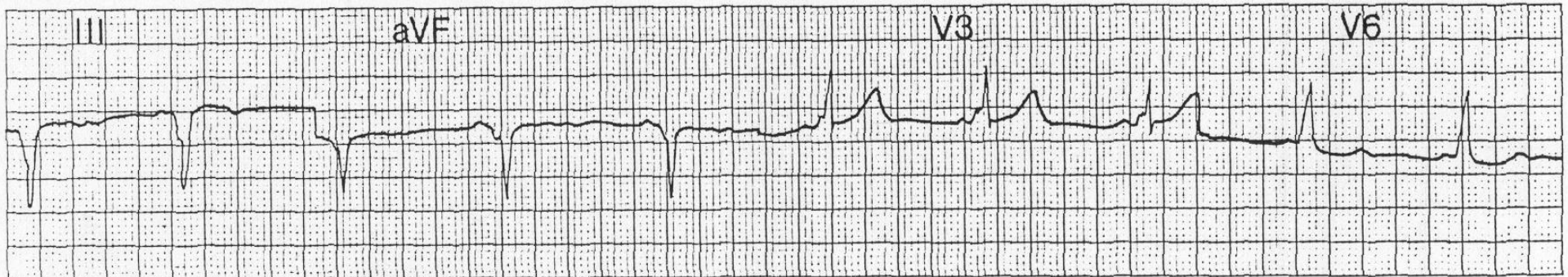
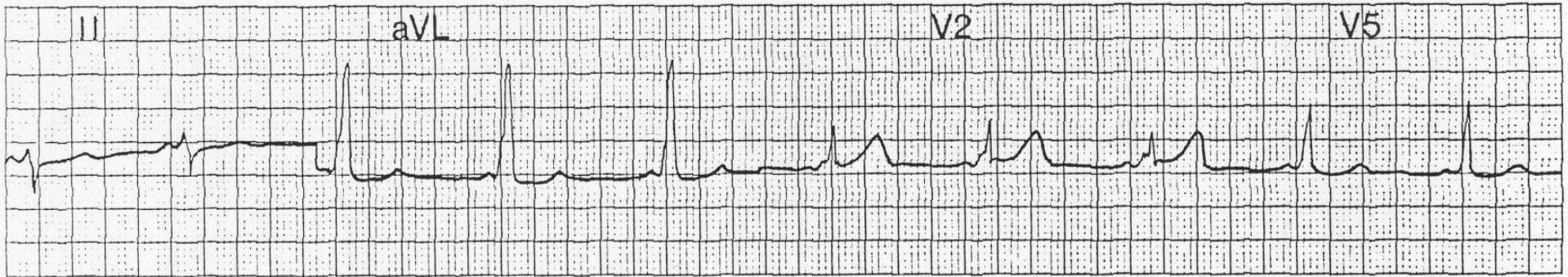
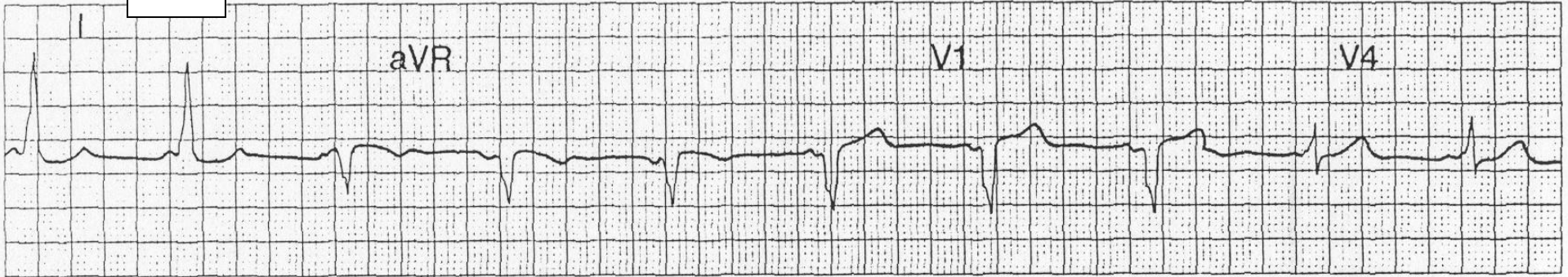
10.



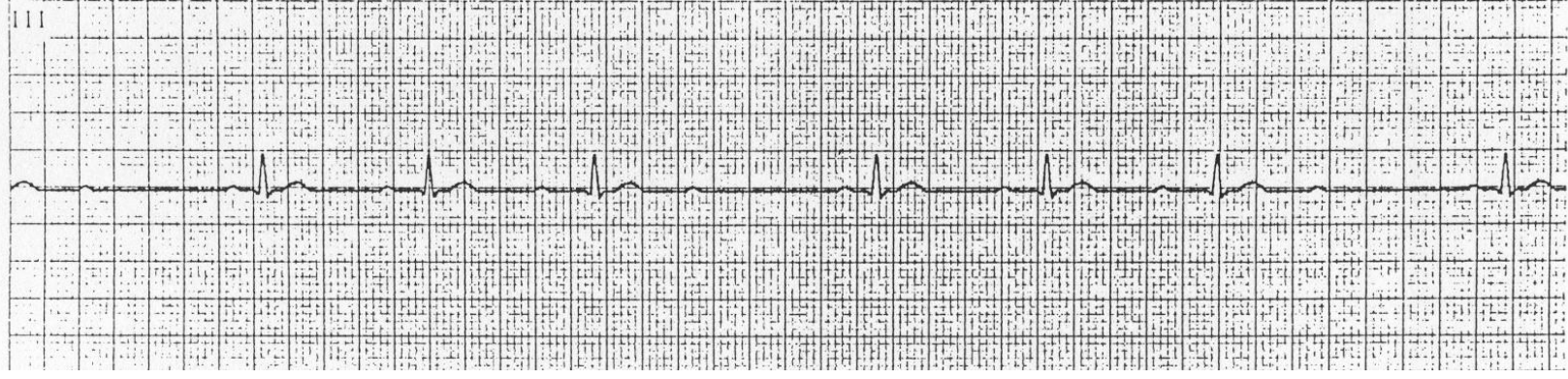
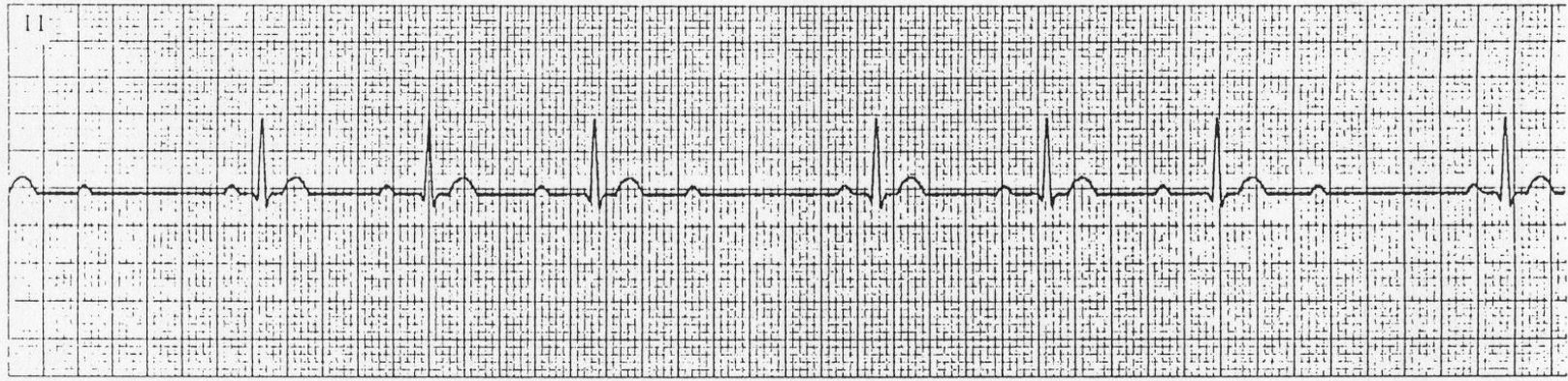
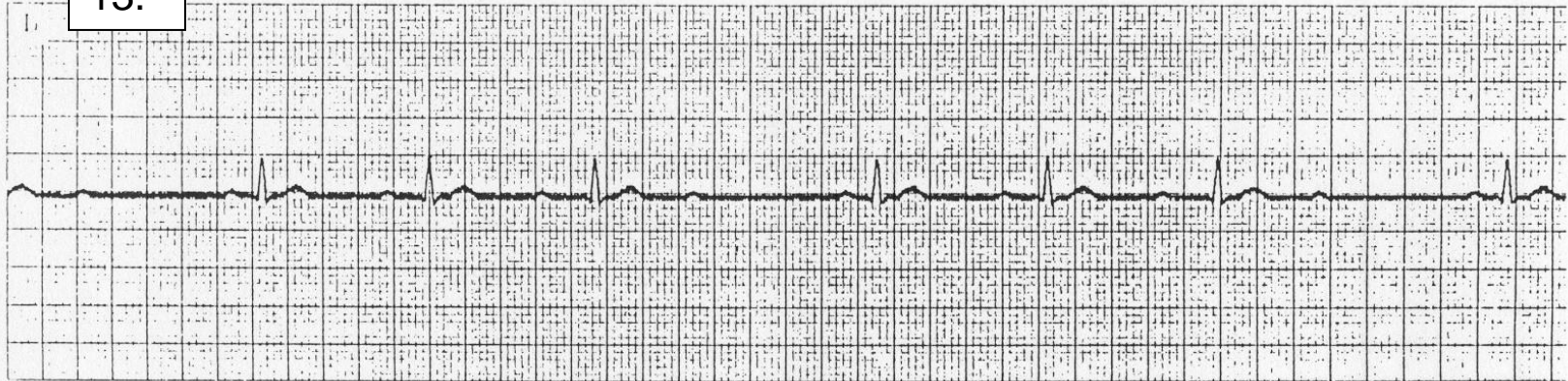11.



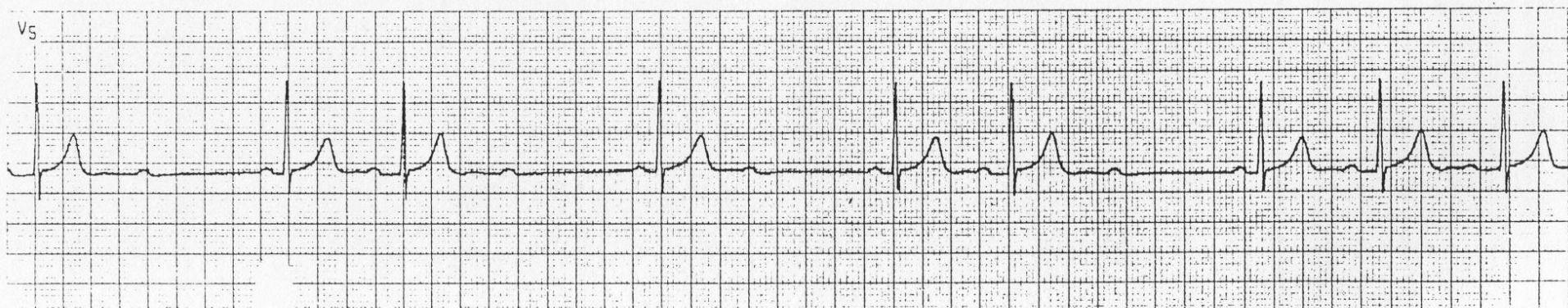
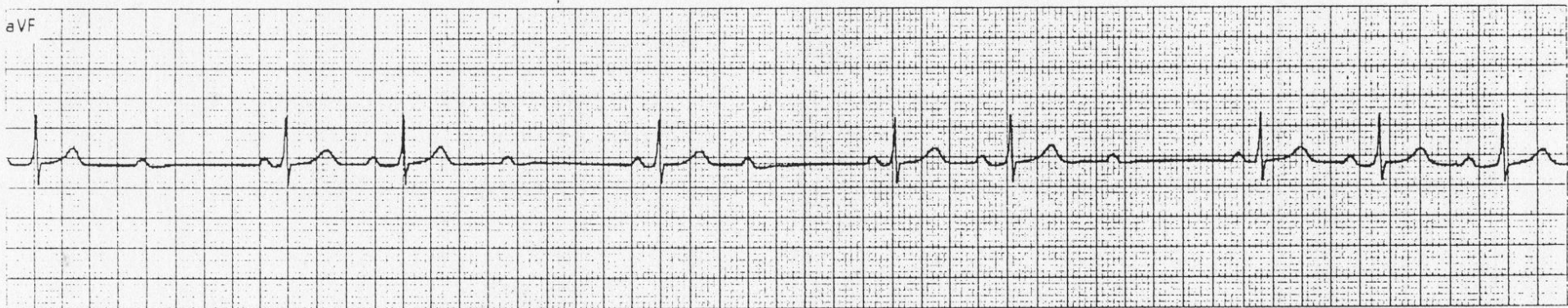
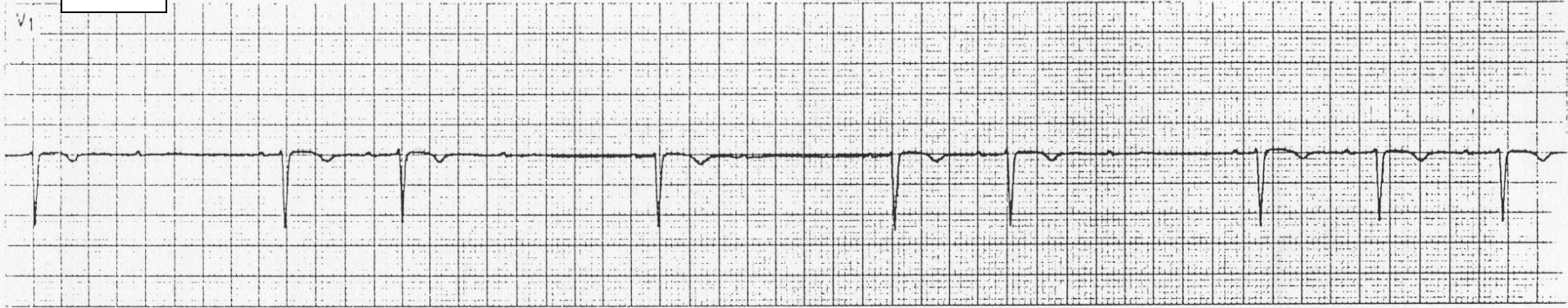
12.



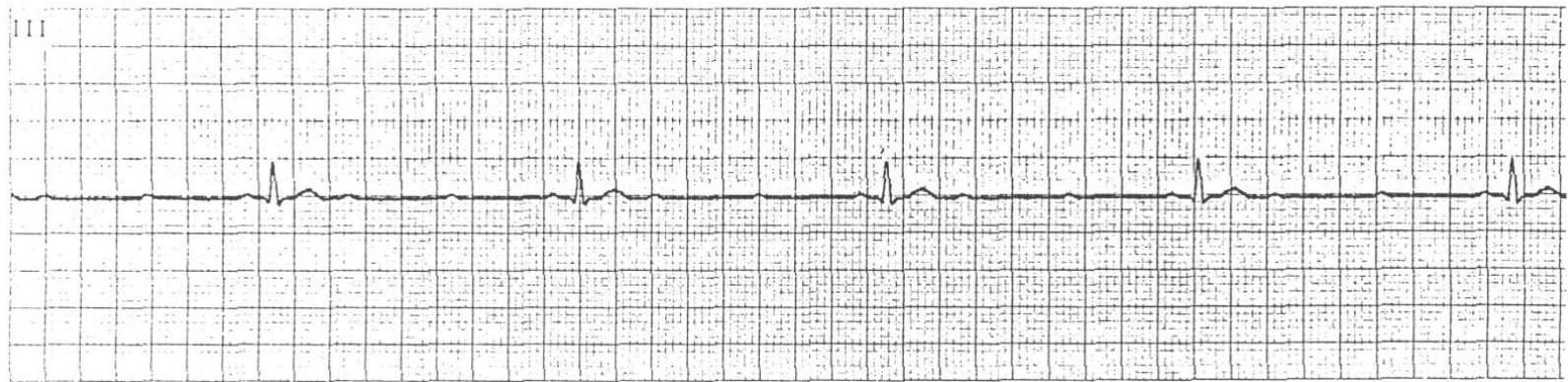
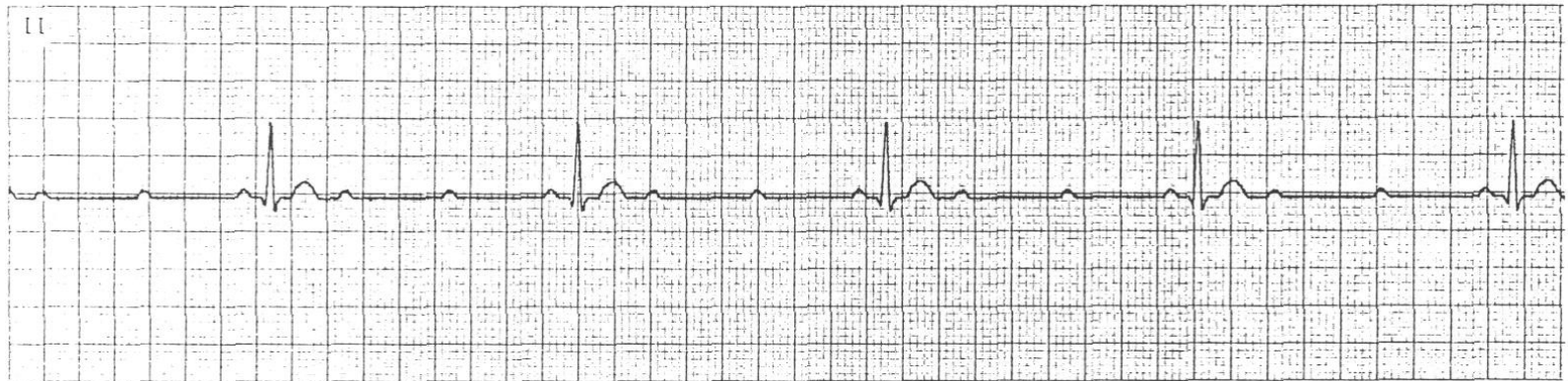
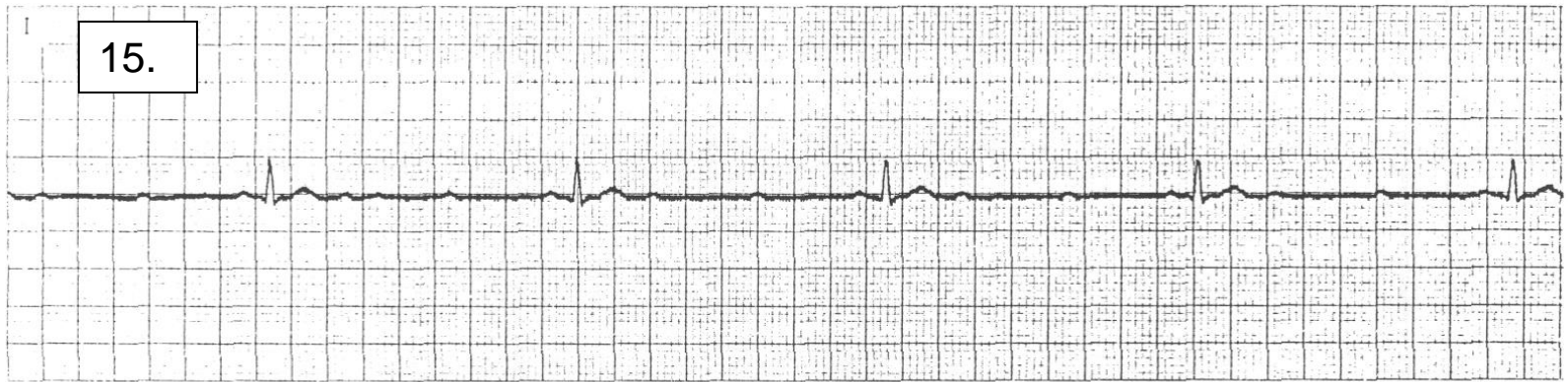
13.



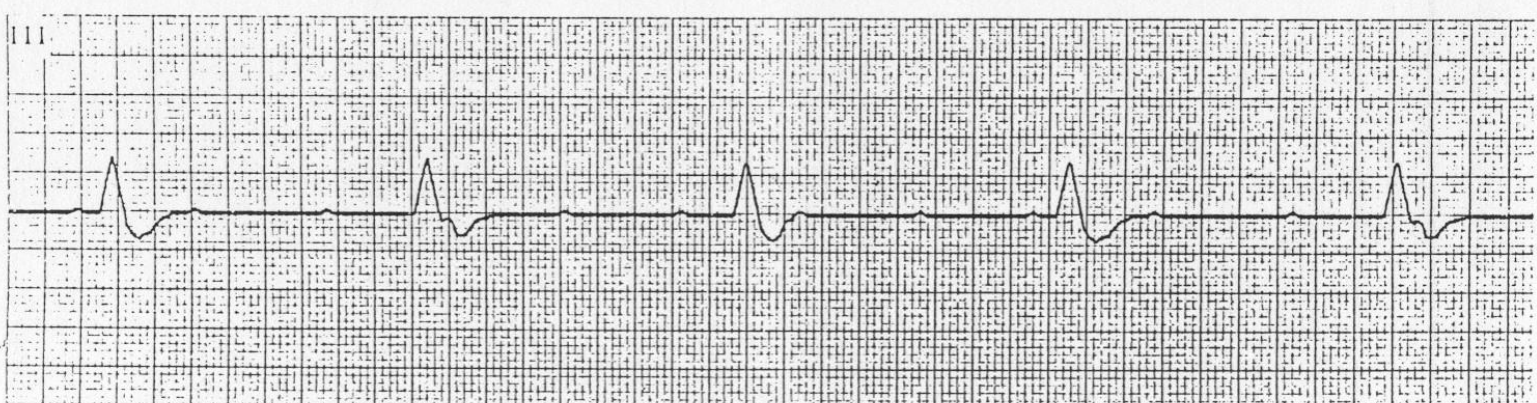
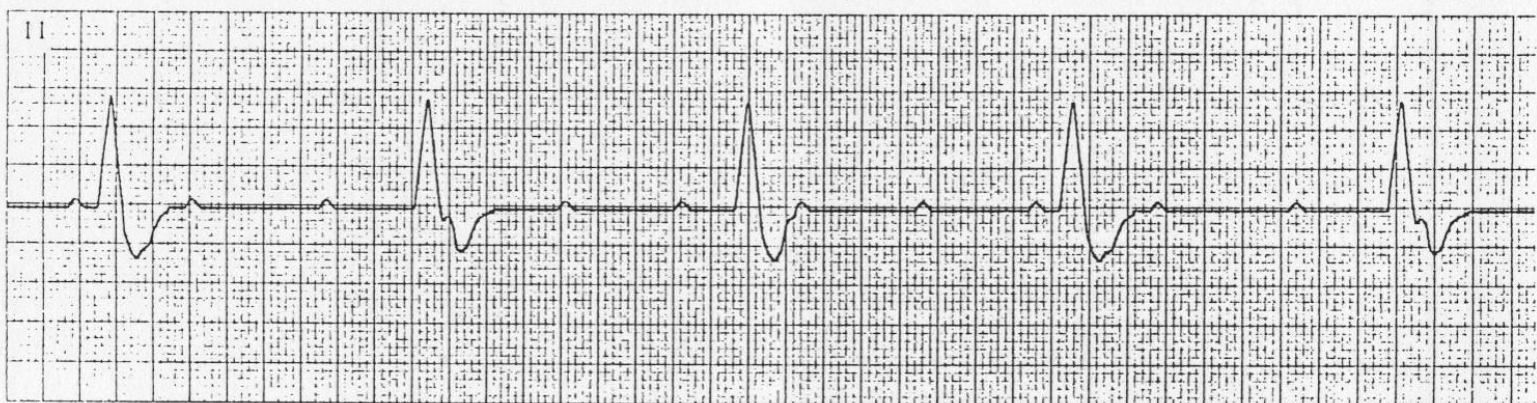
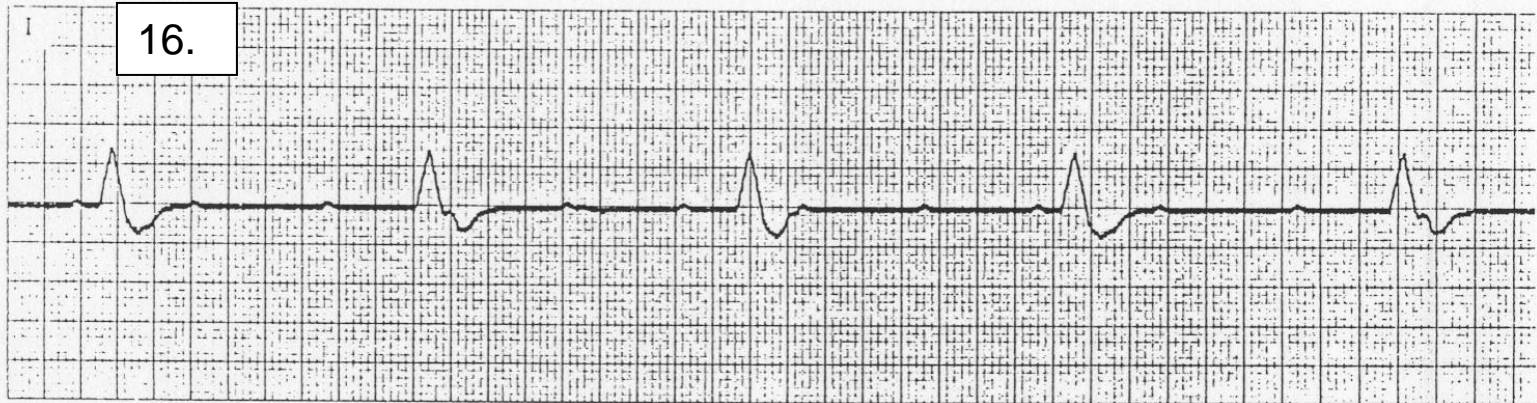
14.

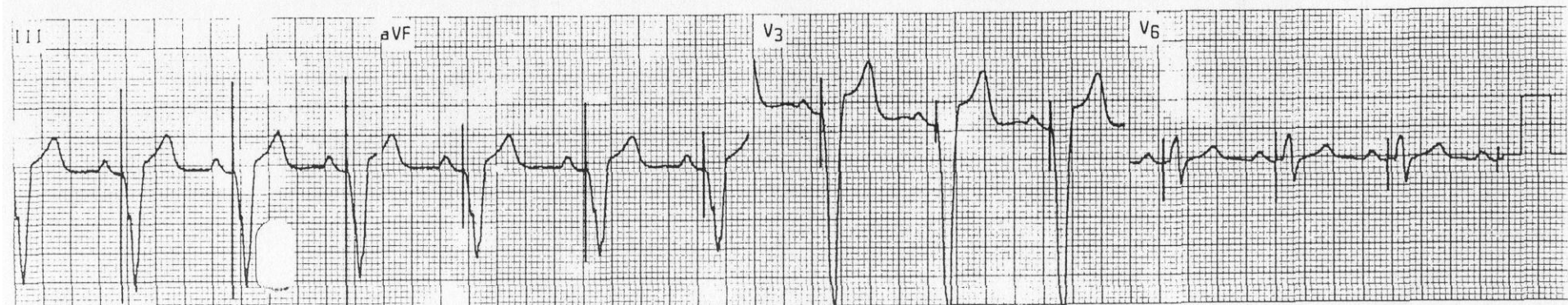
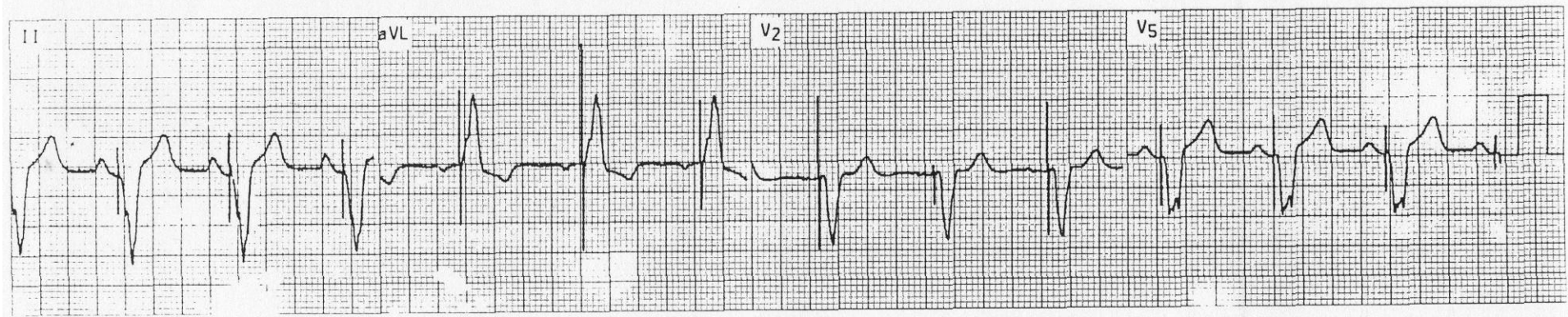
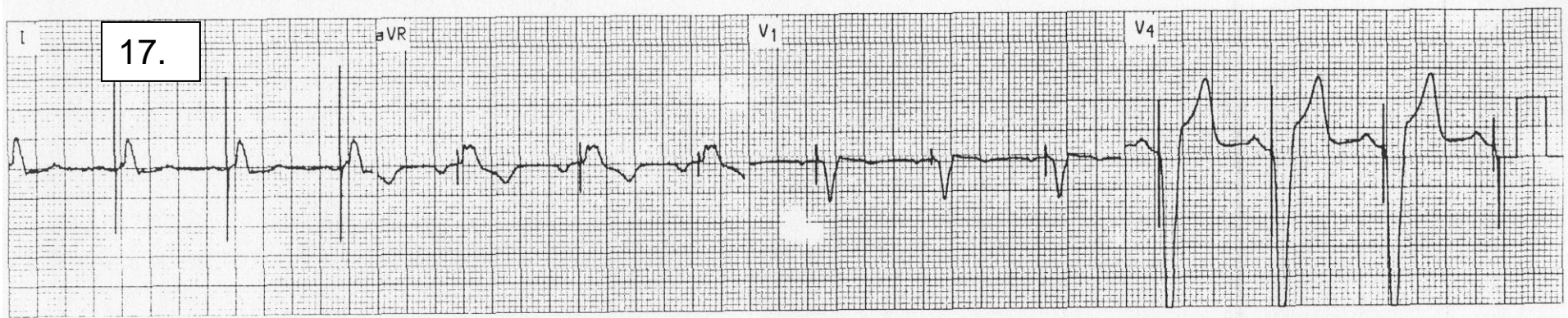


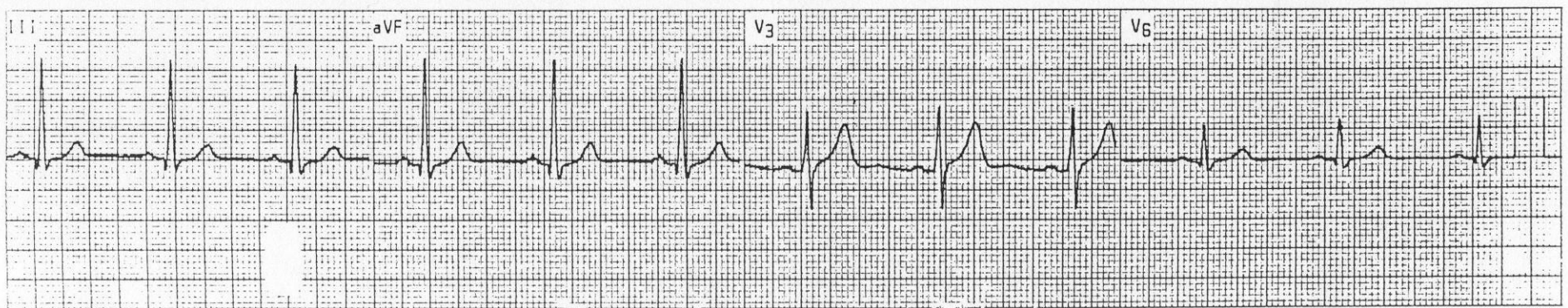
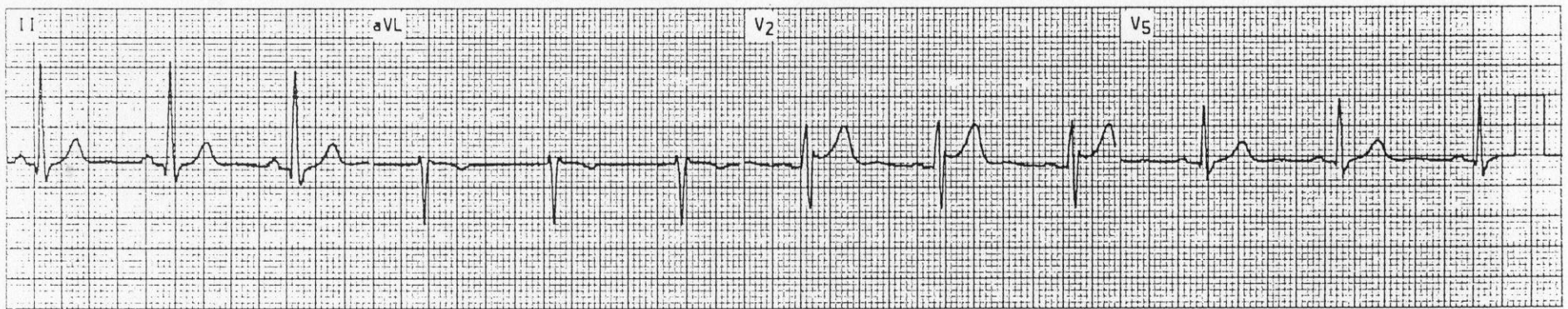
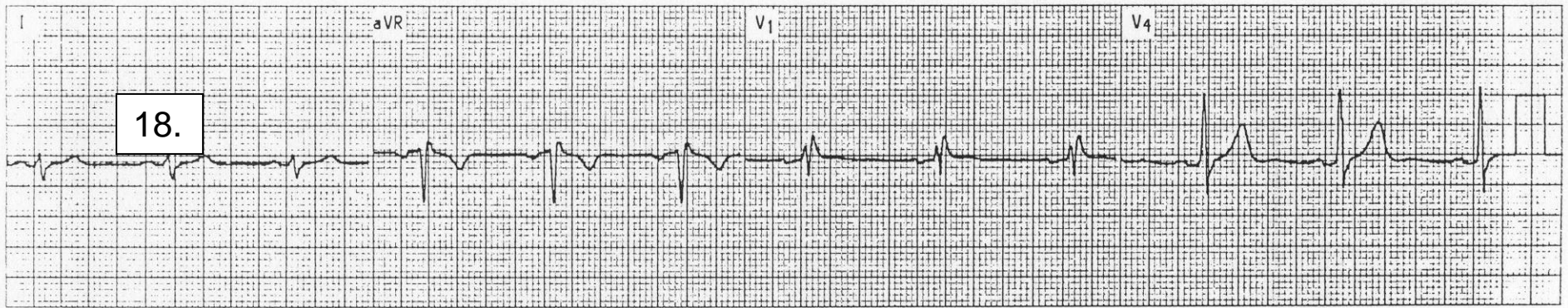
15.



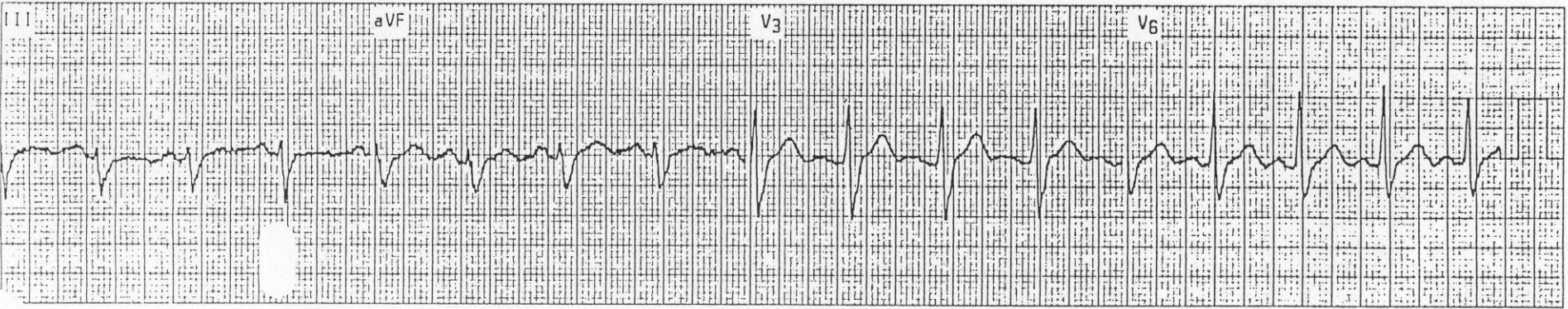
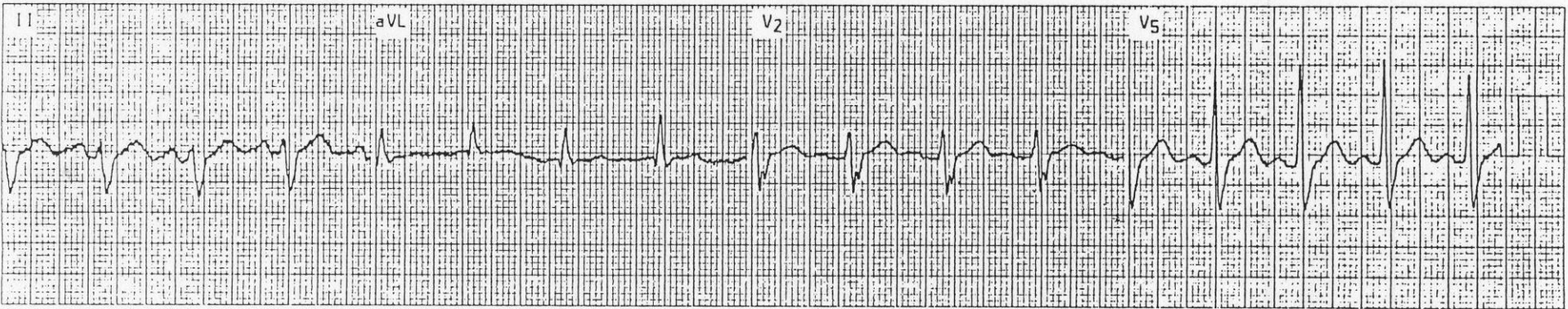
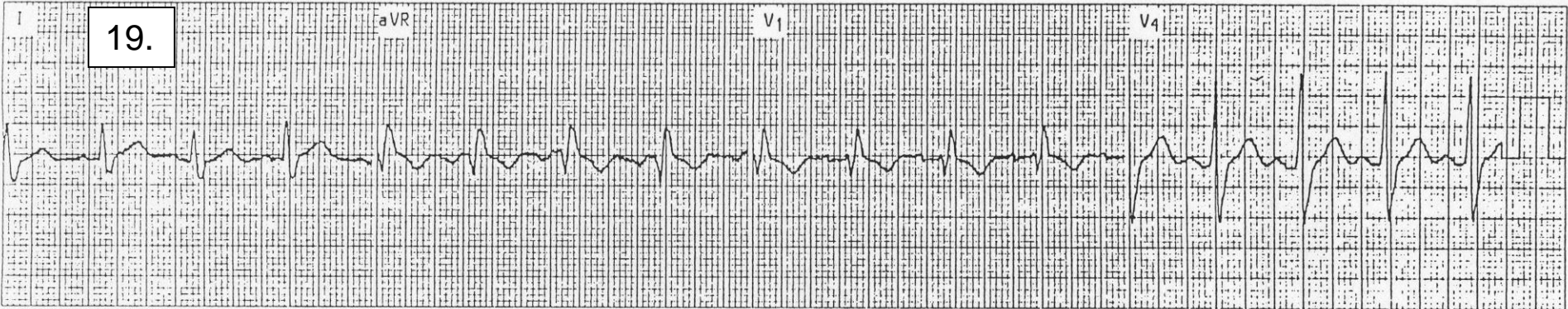
16.



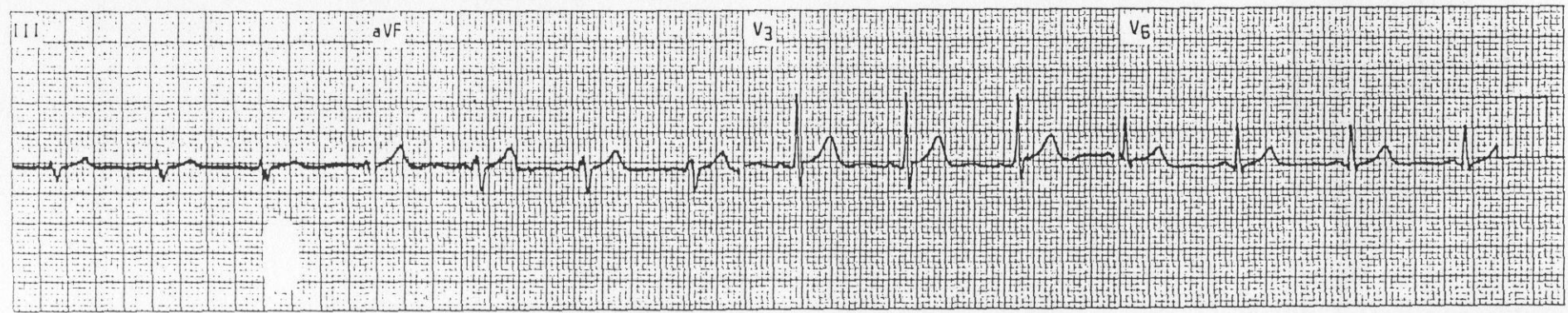
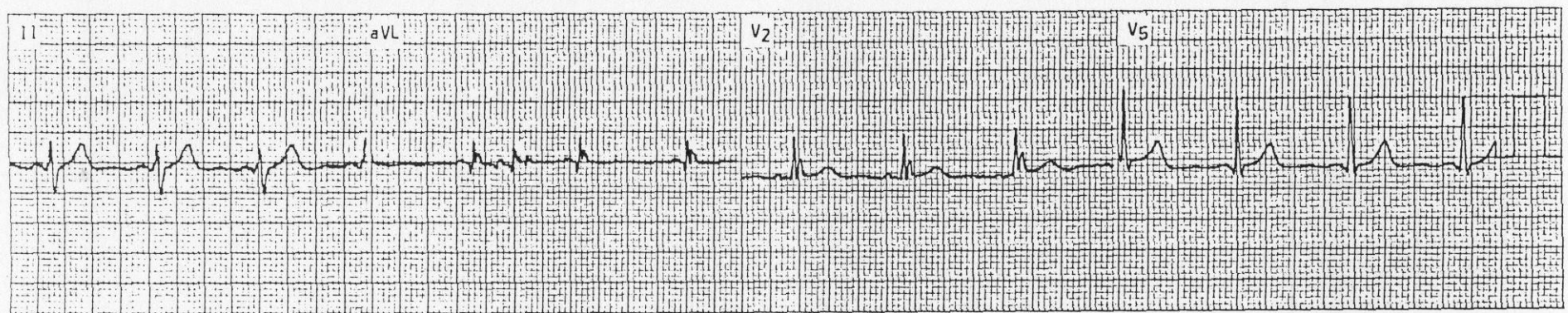
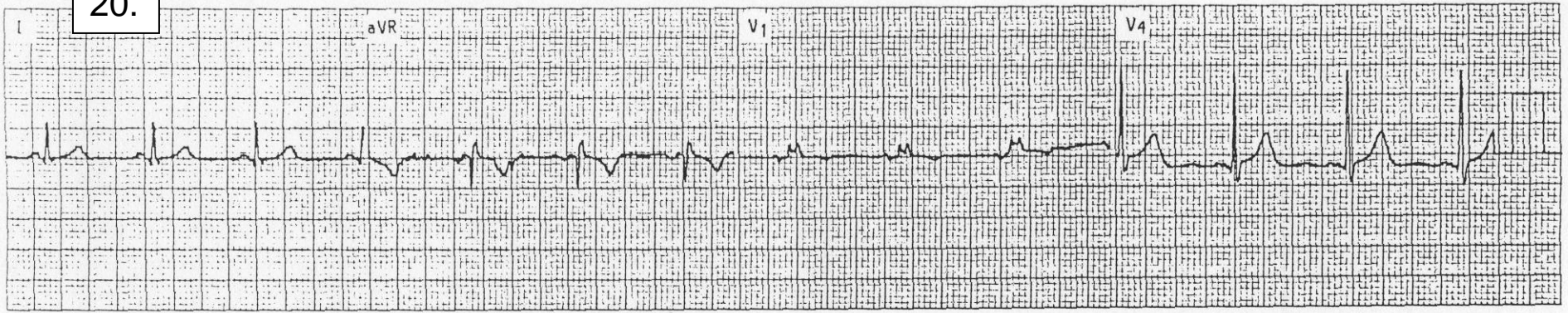




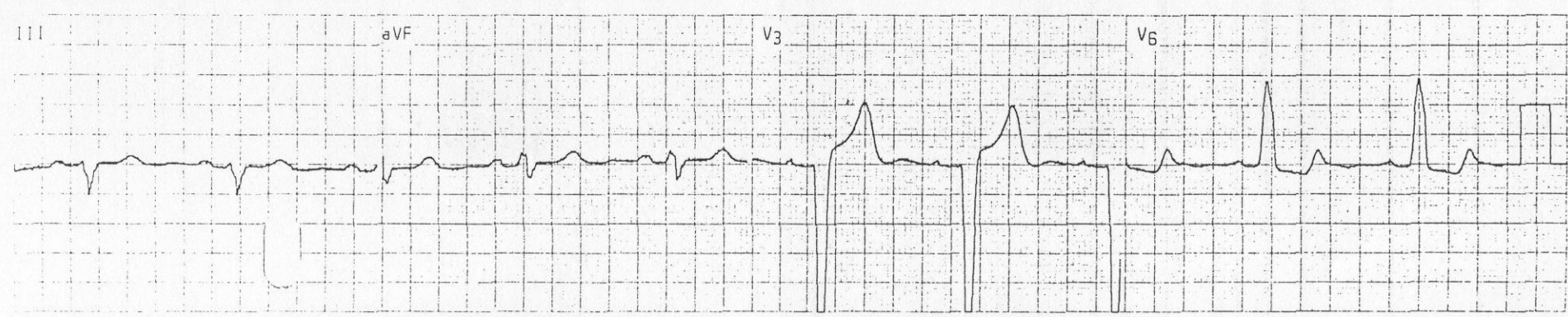
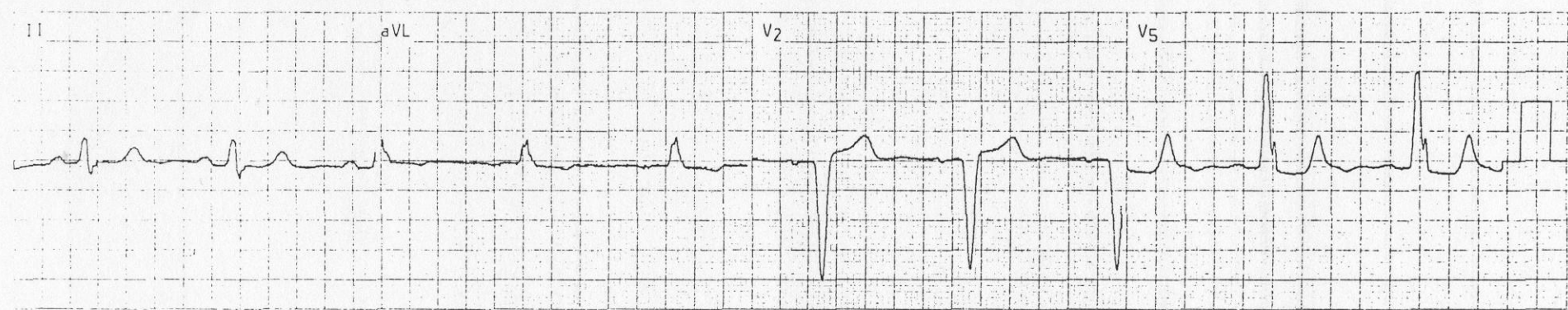
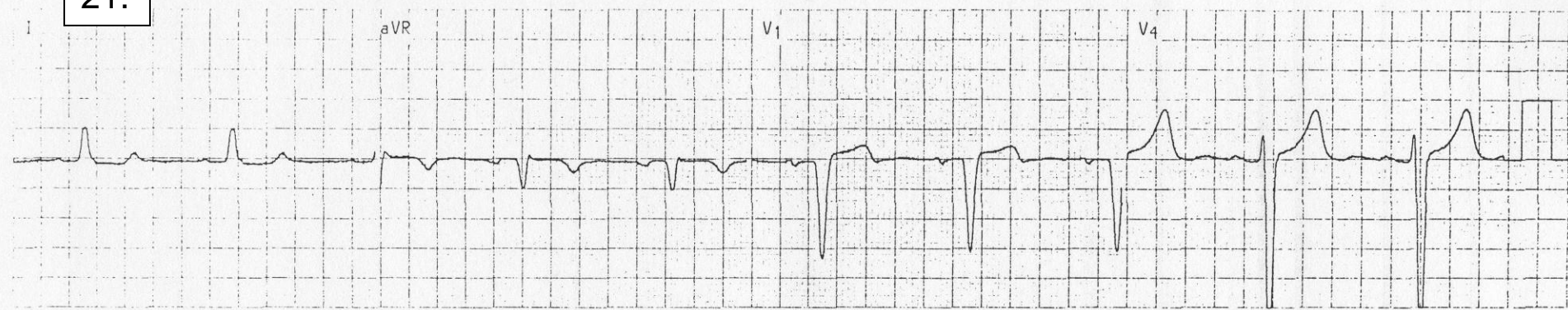
19.



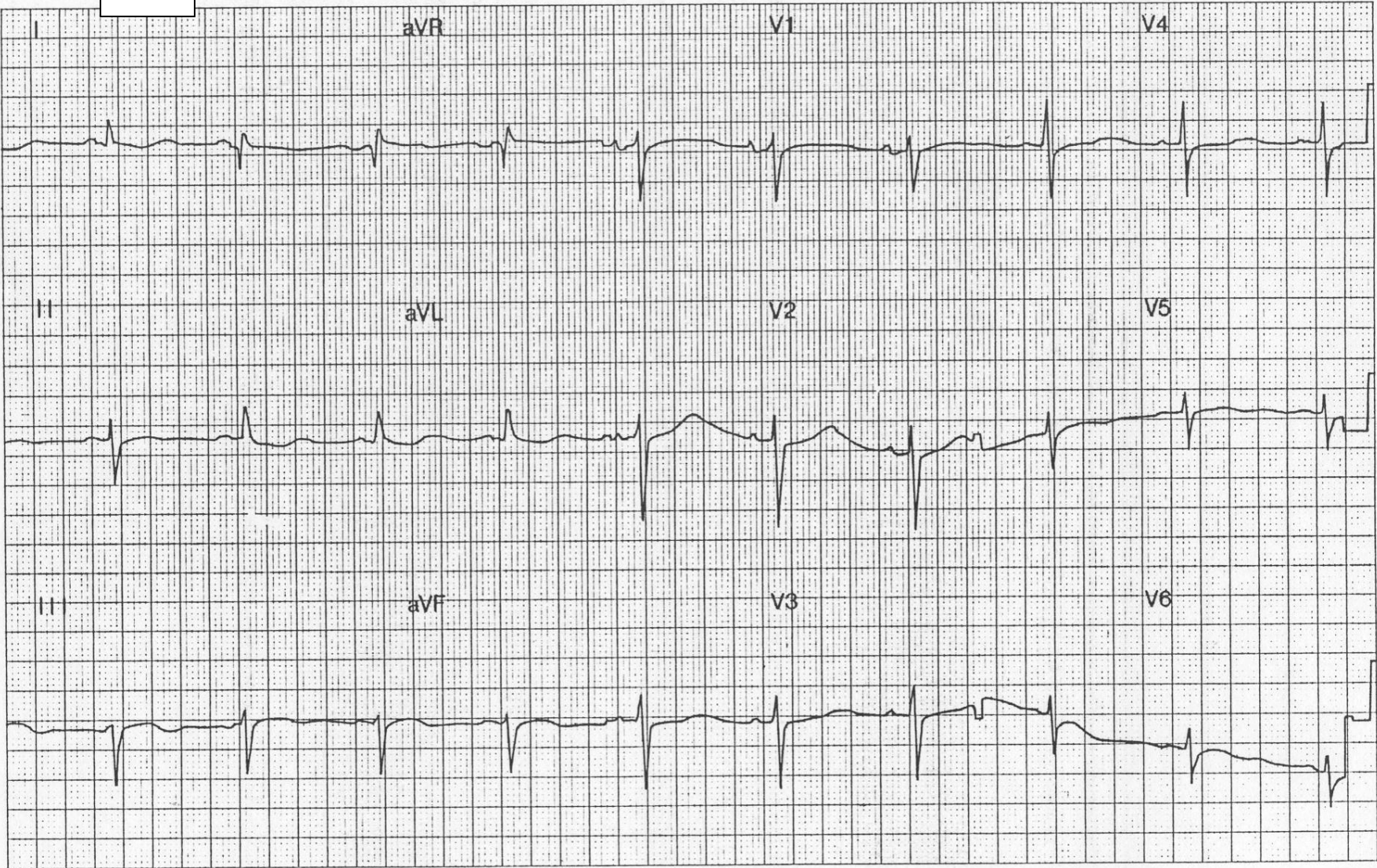
20.



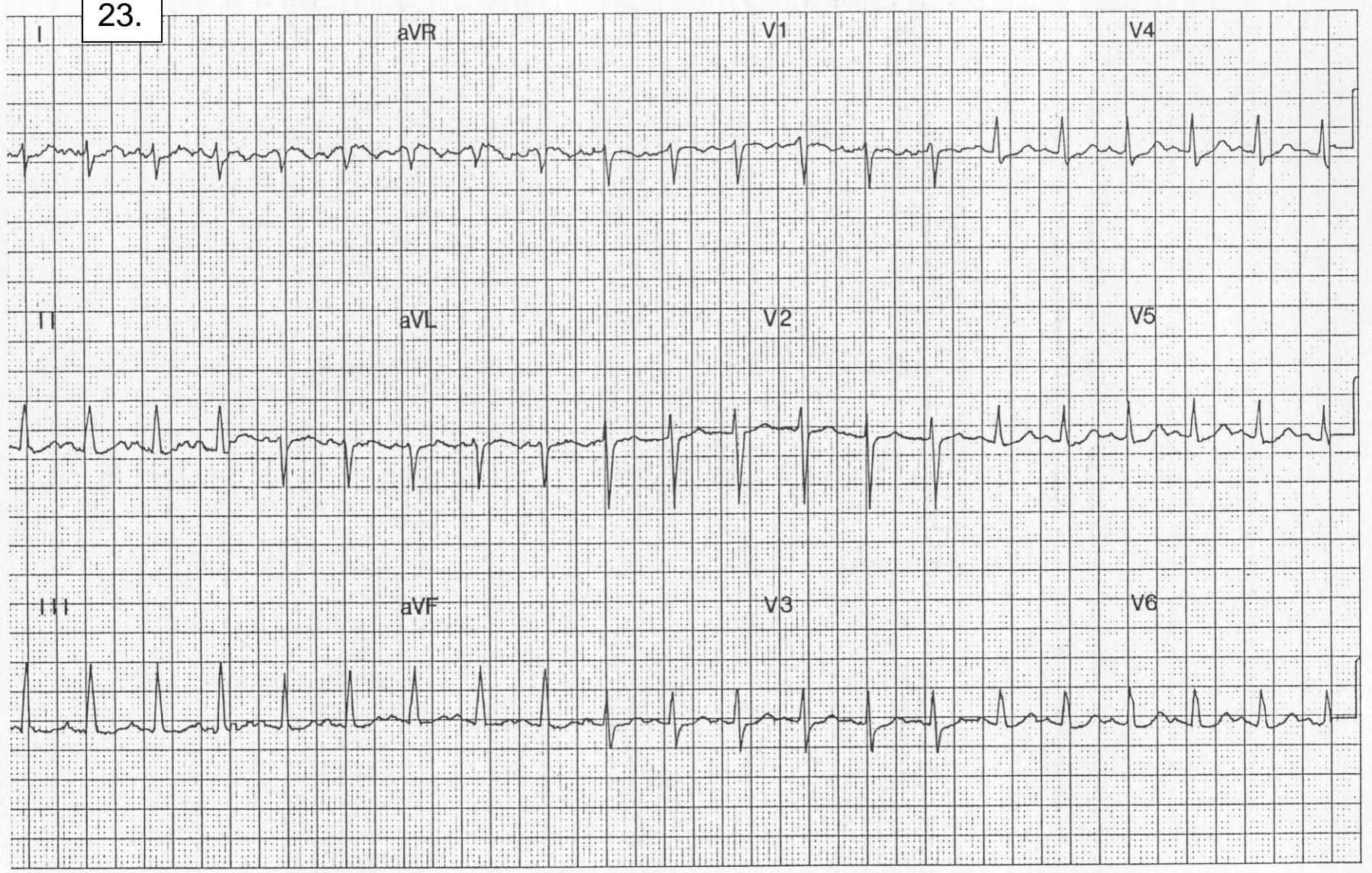
21.



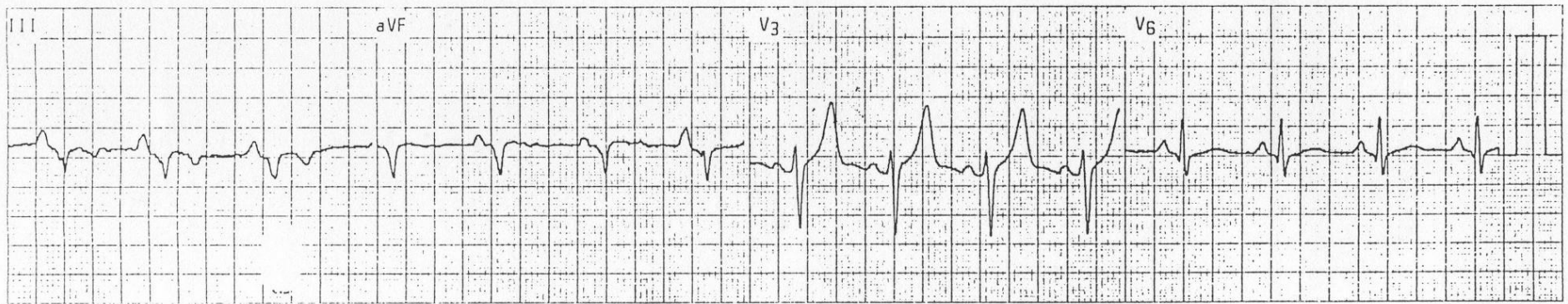
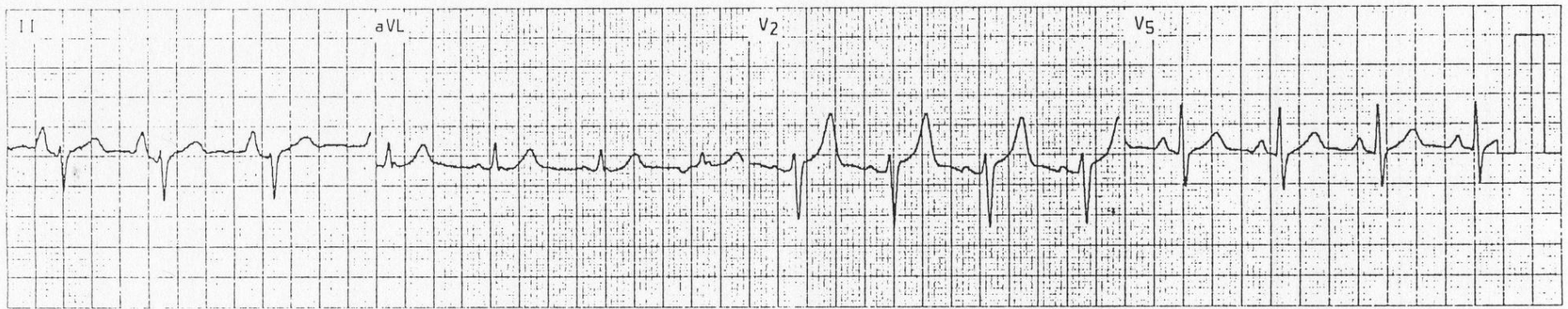
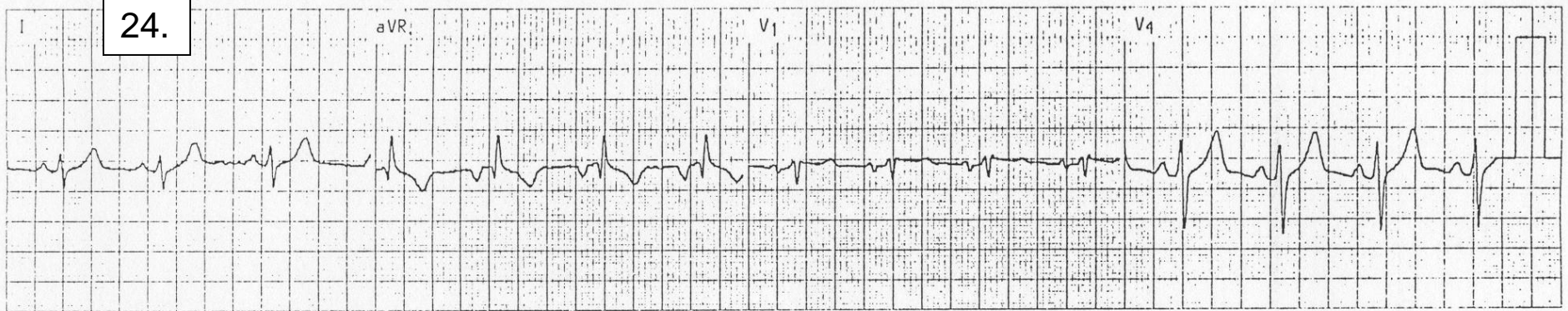
22.



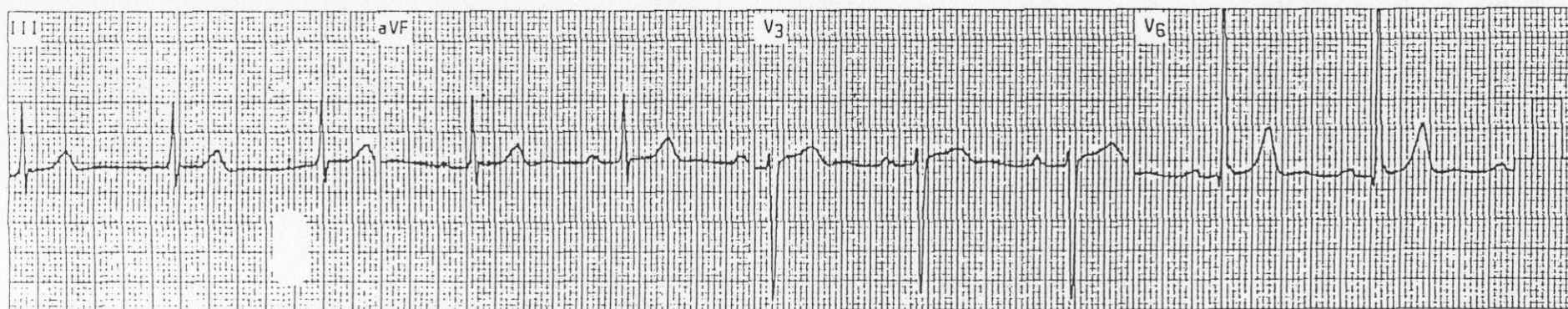
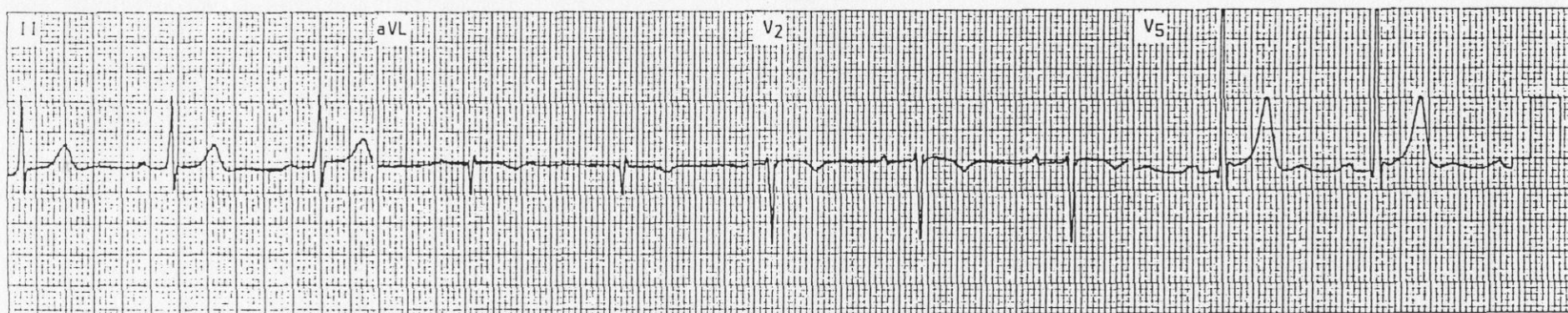
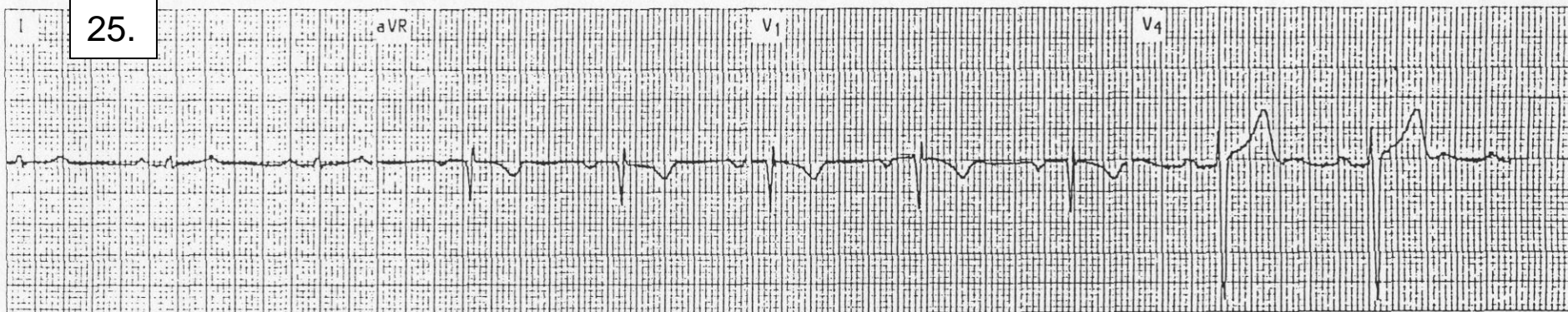
23.



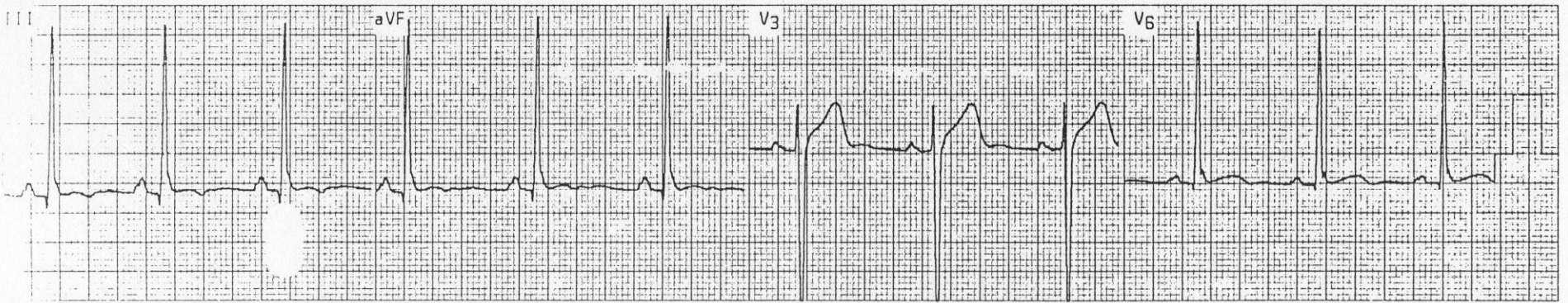
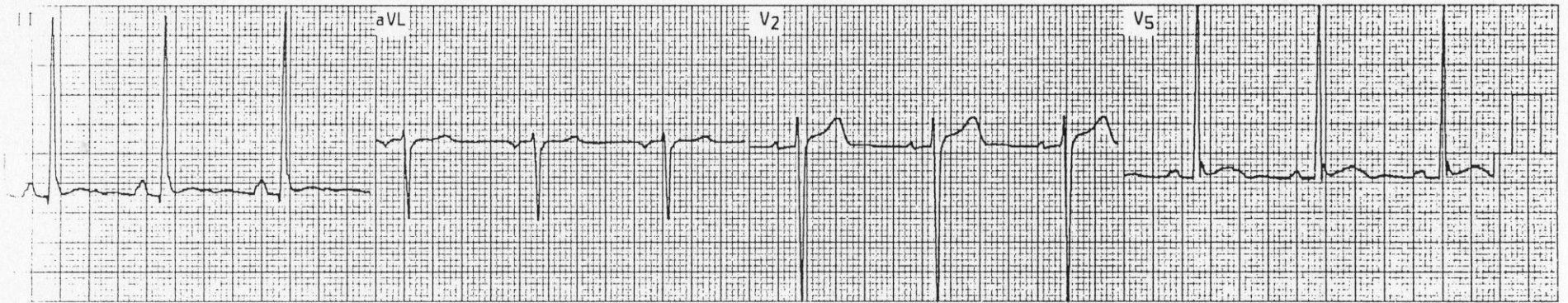
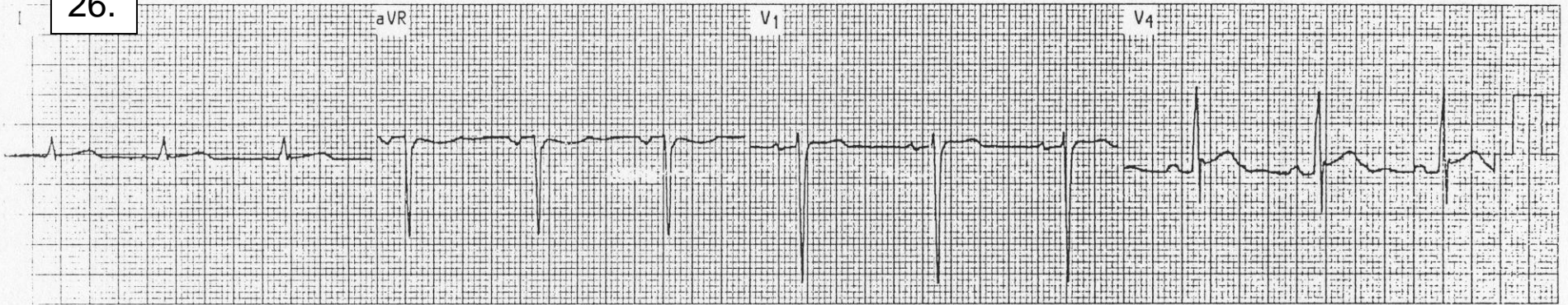
24.



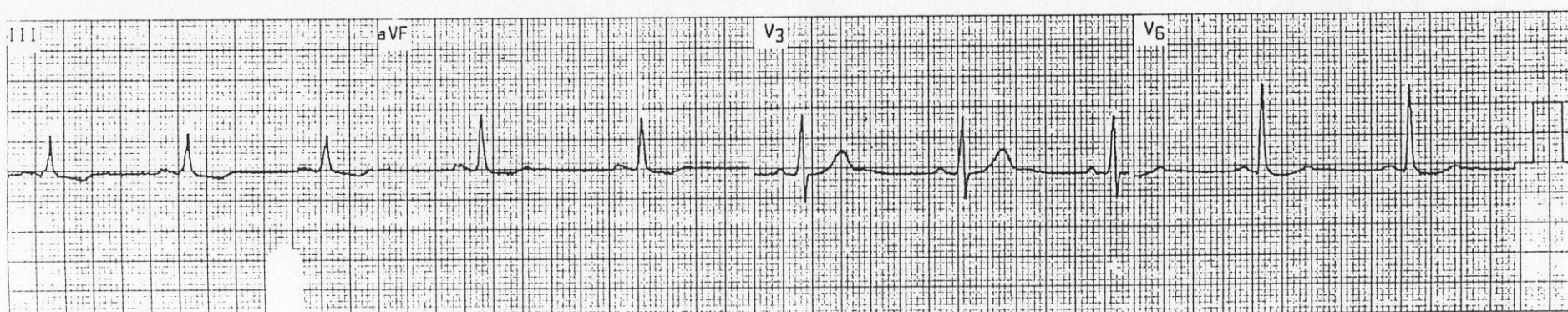
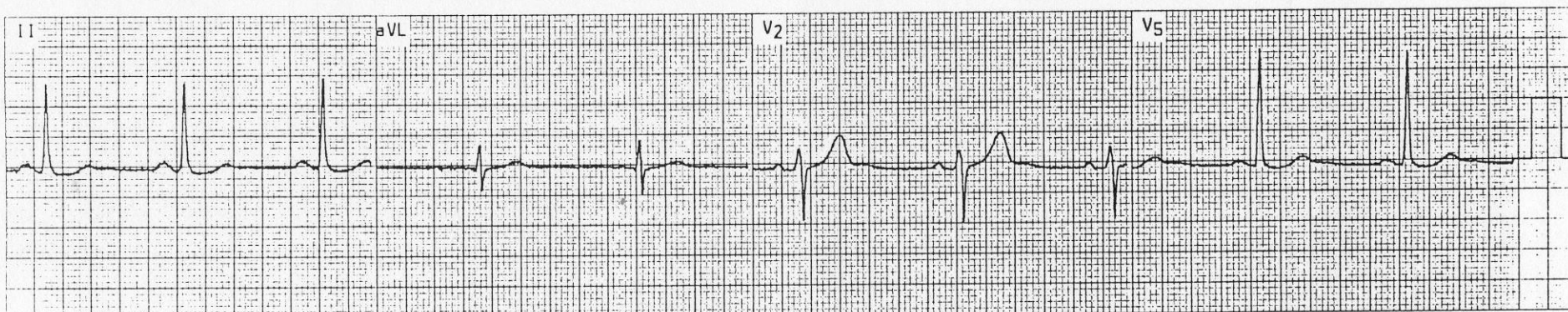
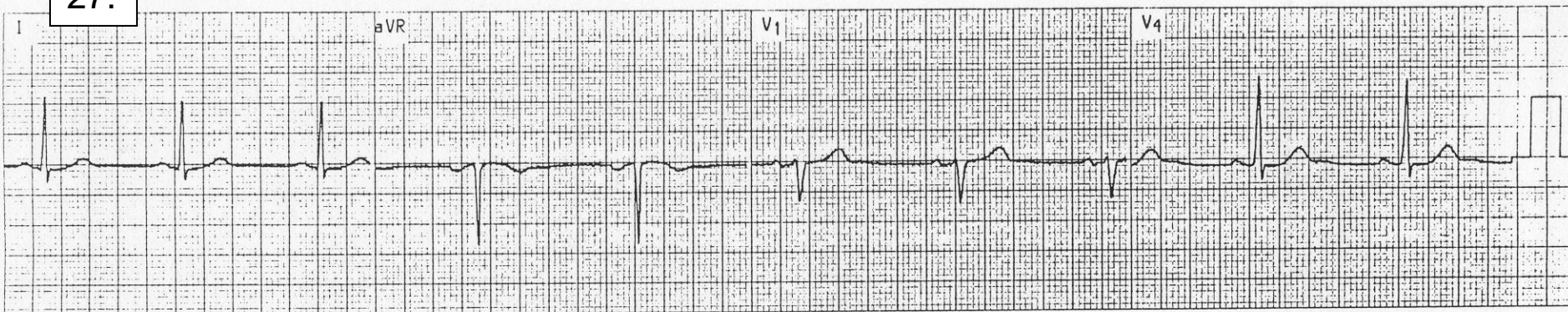
25.



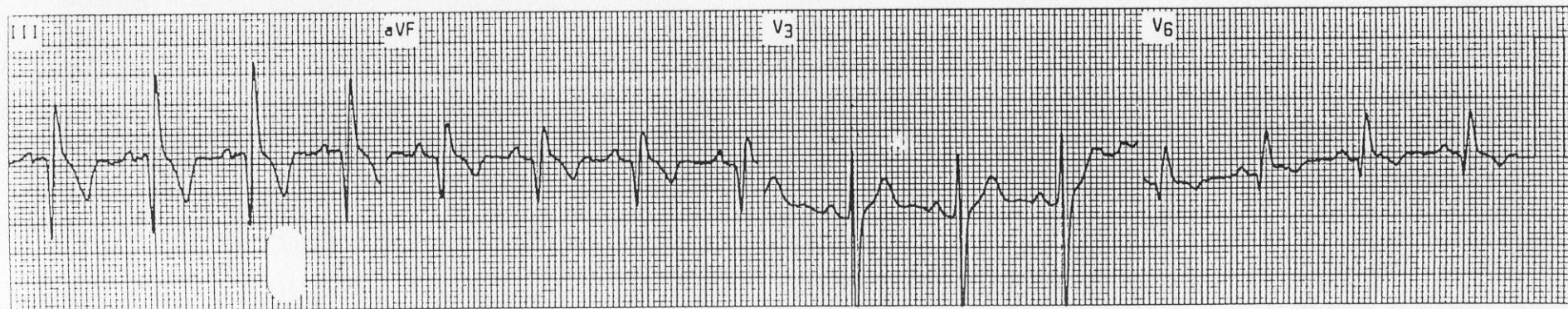
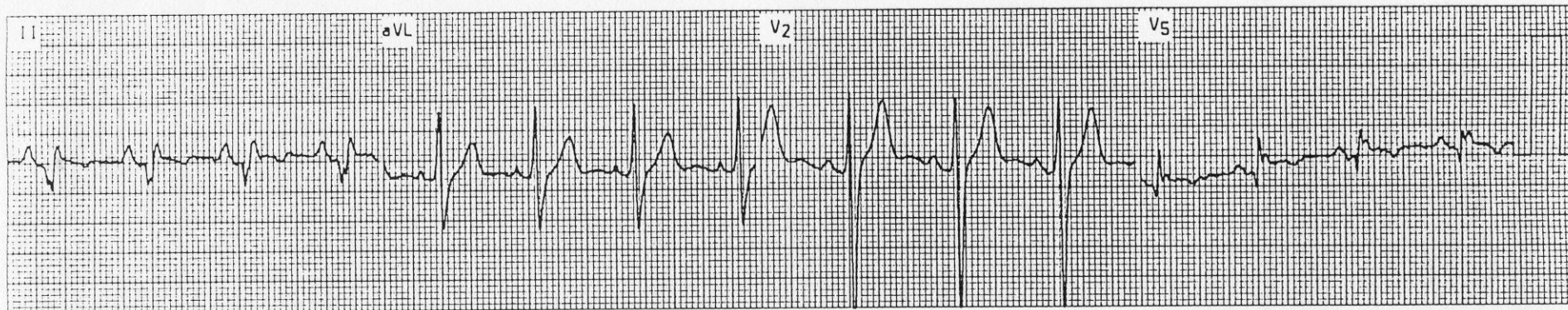
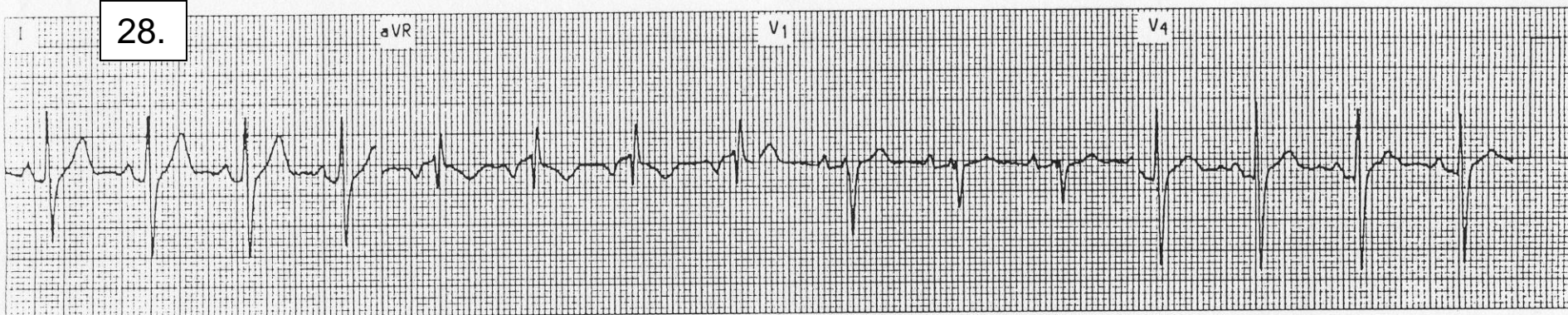
26.



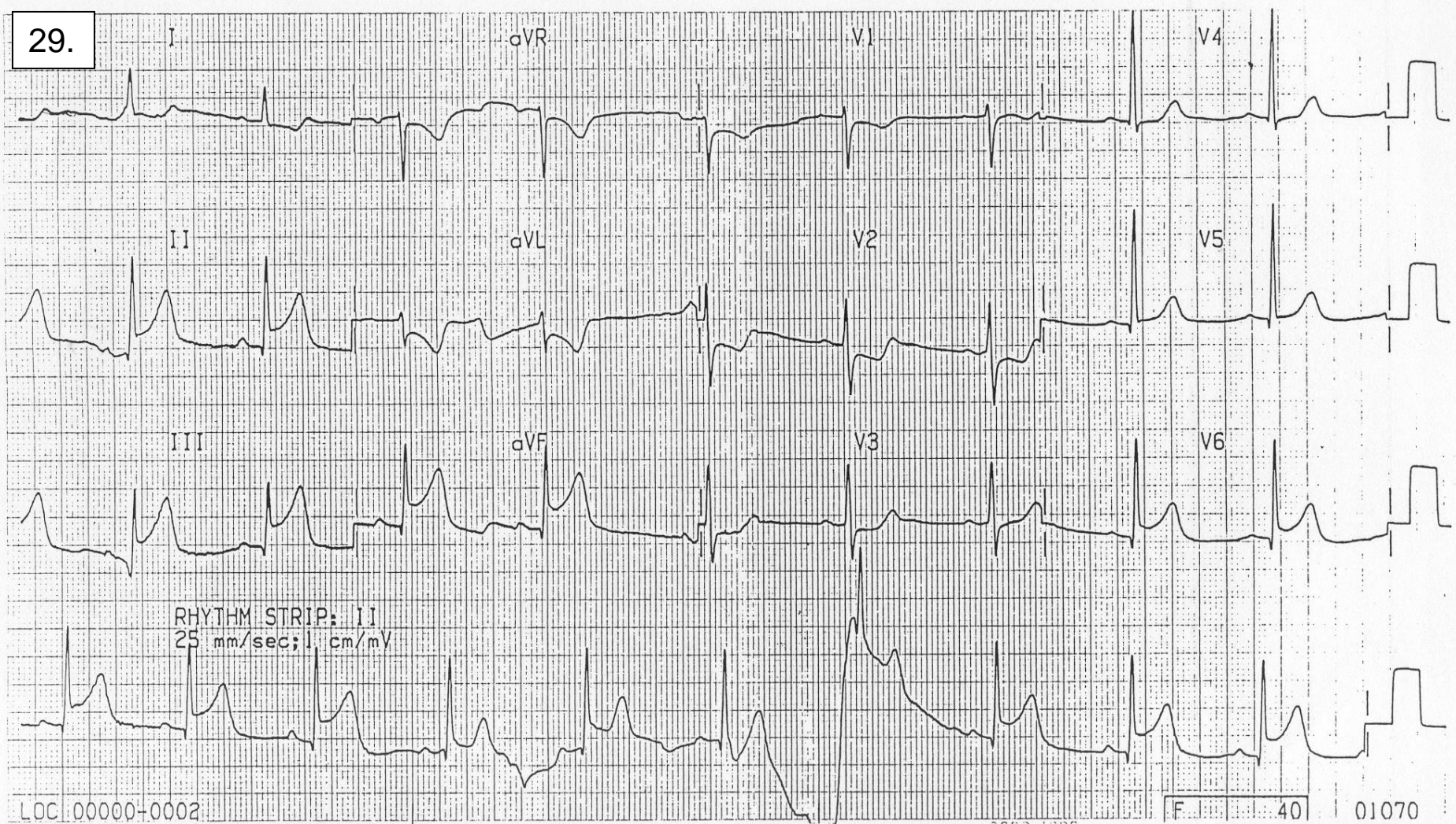
27.



28.



29.

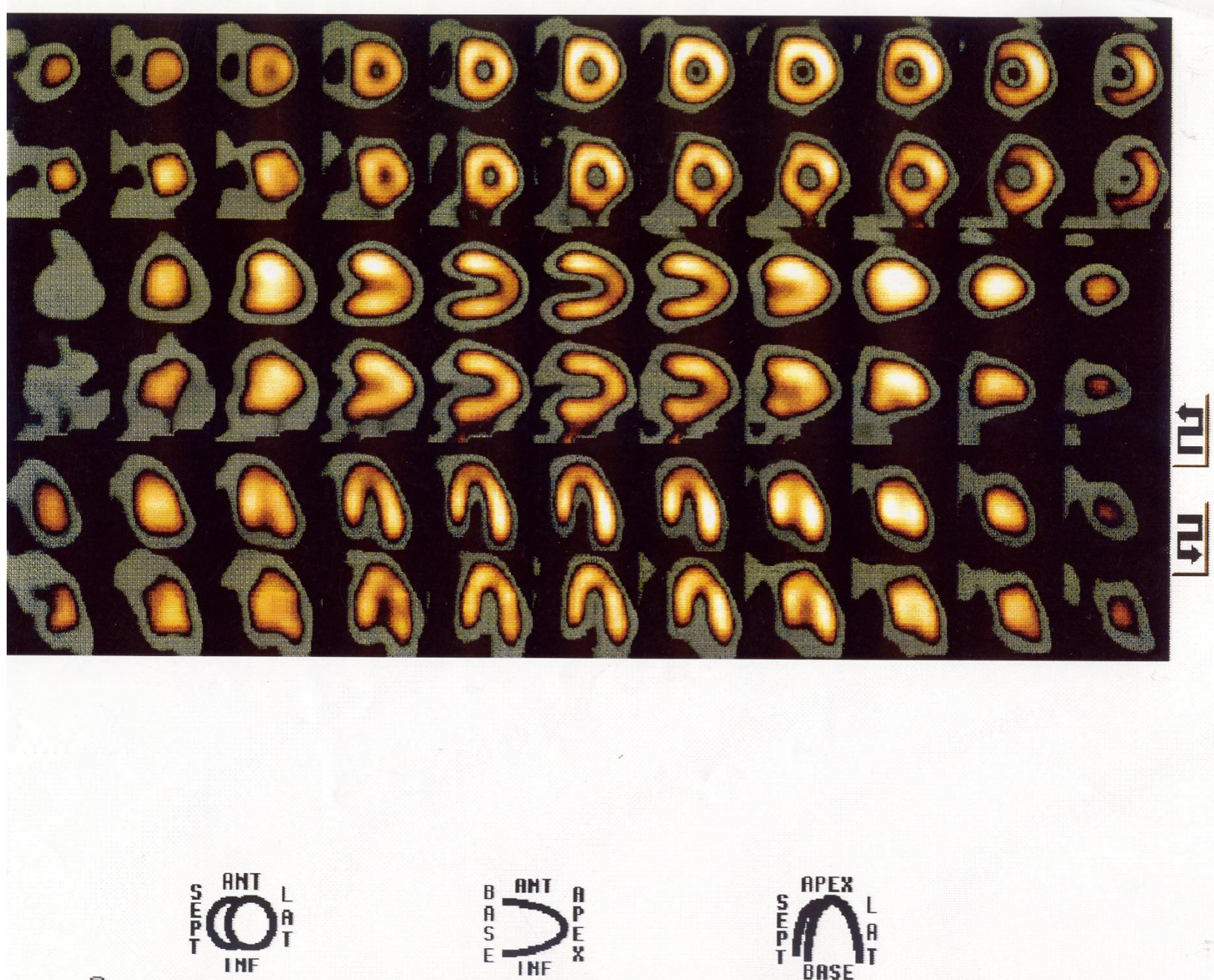


LOC 00000-0002

F 40

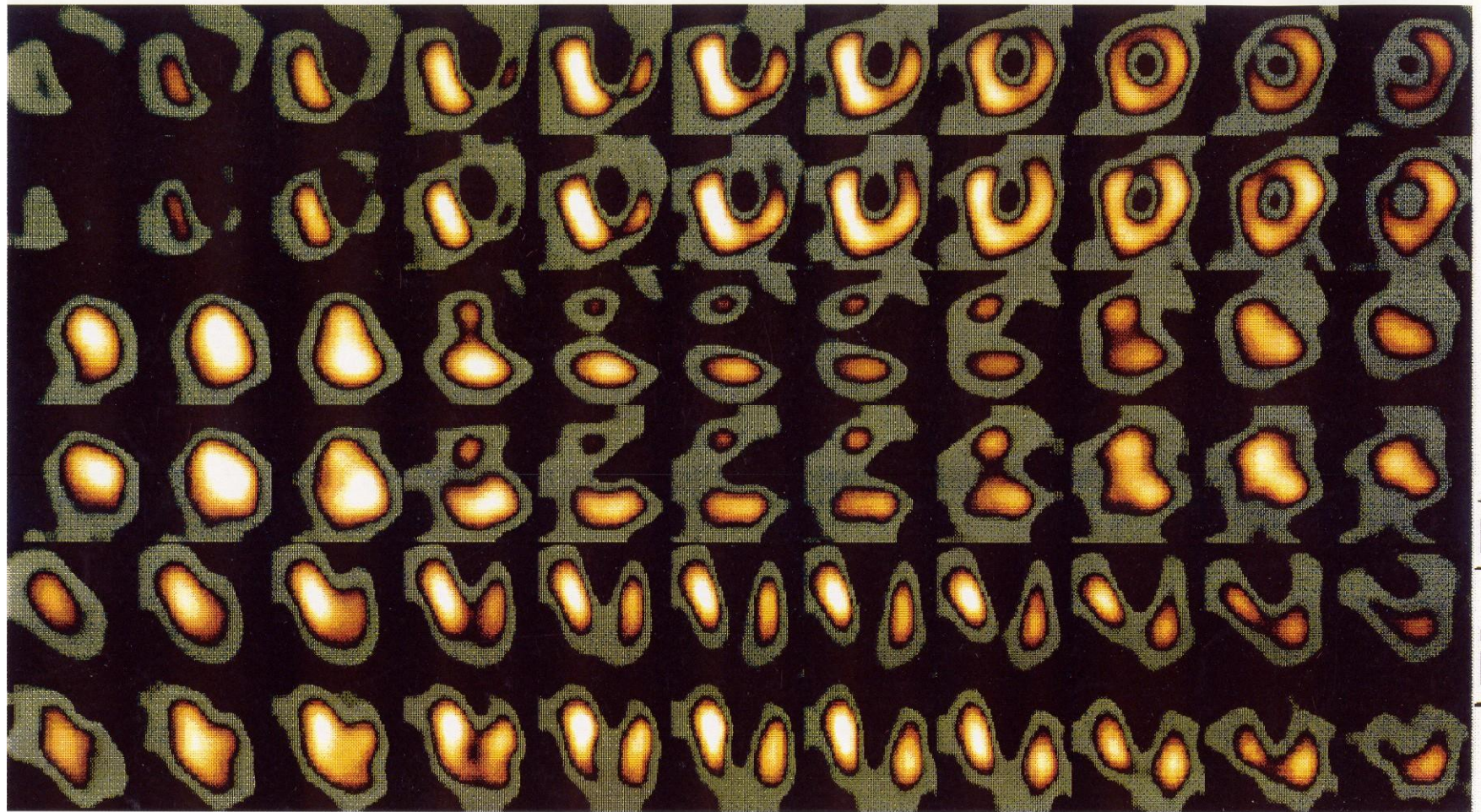01070

30.



Normal Thallium - note full circles and horseshoes corresponding to well perfused myocardium – the brighter the area, the more blood is contained within that area

31.

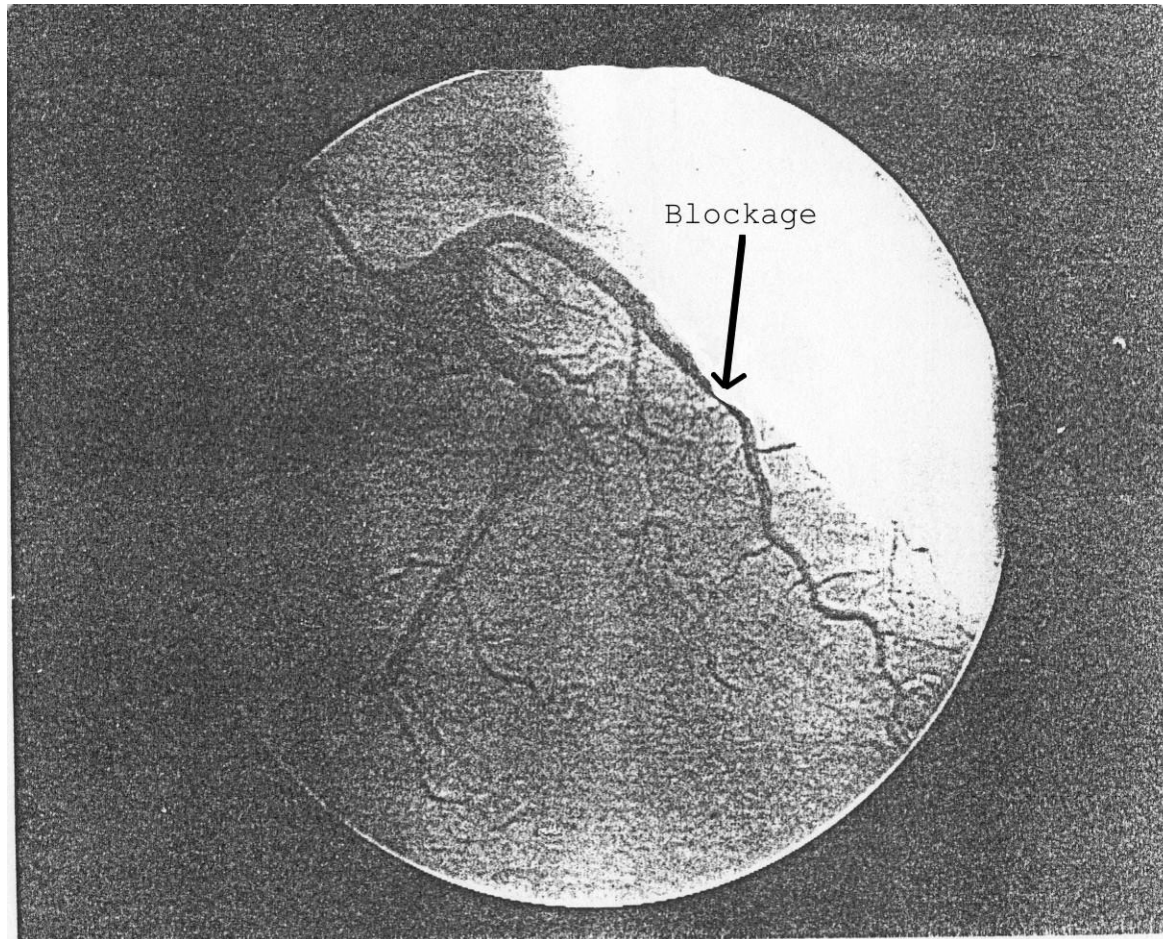


Abnormal Thallium – note incomplete areas of circles and horseshoes corresponding to underperfused myocardium

Heart Catheterization

Note the thinning of the vessel denoted by the arrow....this thinning represents an atherosclerotic plaque

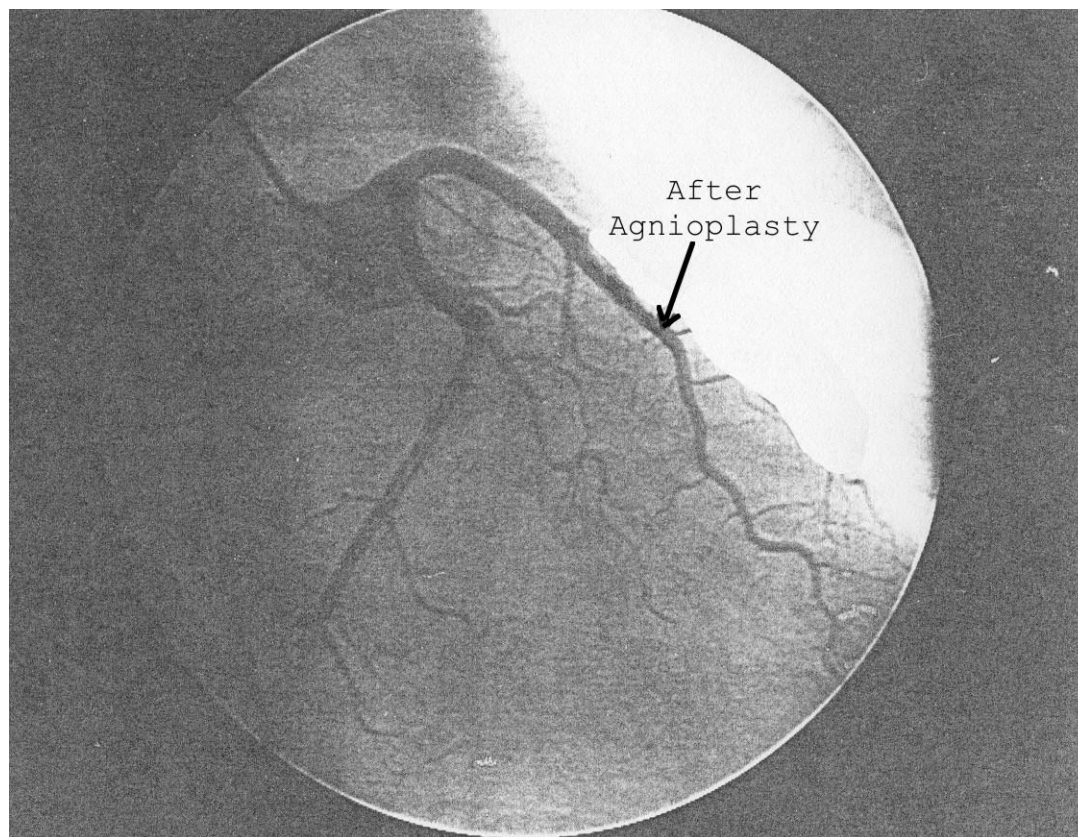
32.



This is the same artery as on the previous page but after PTCA procedure (Percutaneous Transluminal Coronary Angioplasty)

Note the increased diameter of the coronary artery

33.



ECG : Supine - within normal limits (WNL)

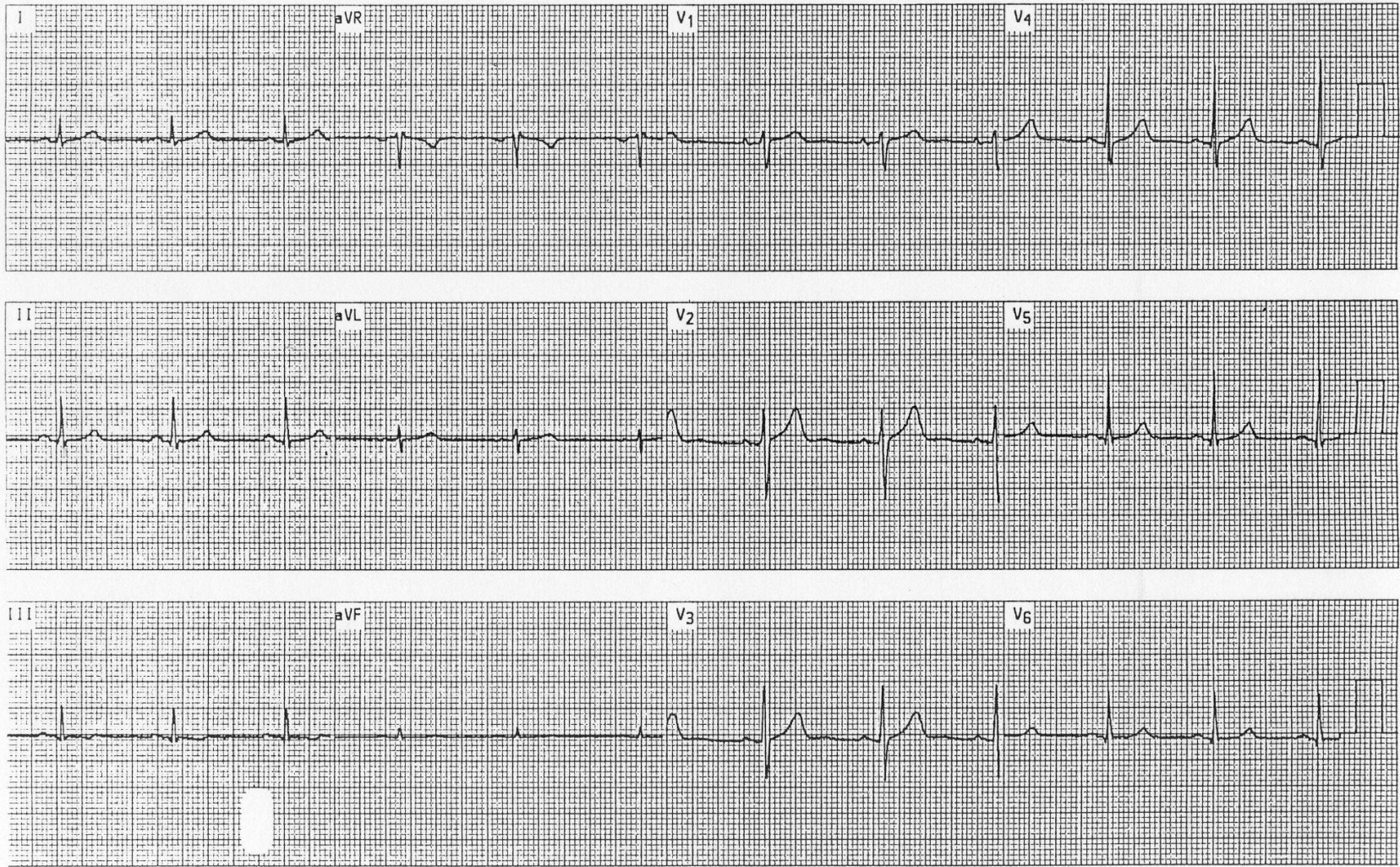
PR=.16 QRS=.08 QT=.36

Axis=slightly >.60 degrees based on AVL being the most equiphase and slightly more negative

BP: 126/80

Comments : Note the slight increase in BP when going from supine to standing (next page). At the instant the body position changes, venous return is reduced causing a drop in cardiac output and BP. Baroreceptors sense this and respond by increasing the heart rate. Cardiac output and BP then increase to a level exceeding that of the supine position.

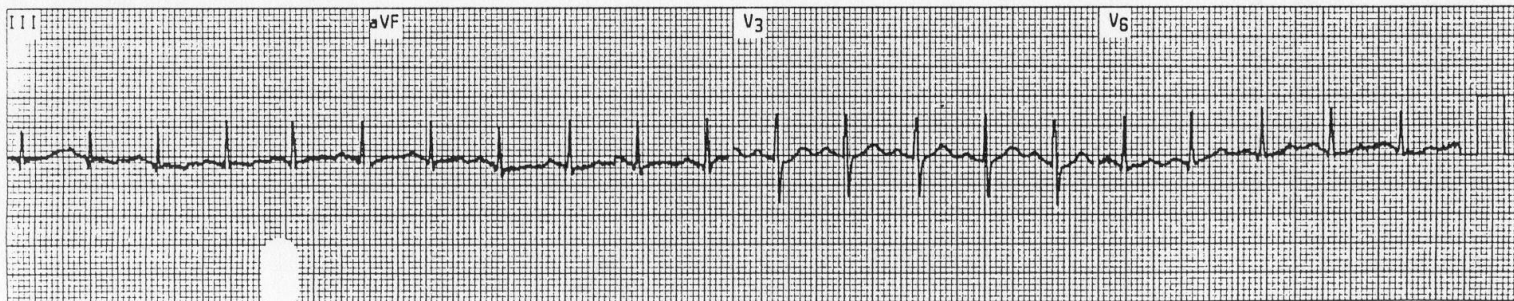
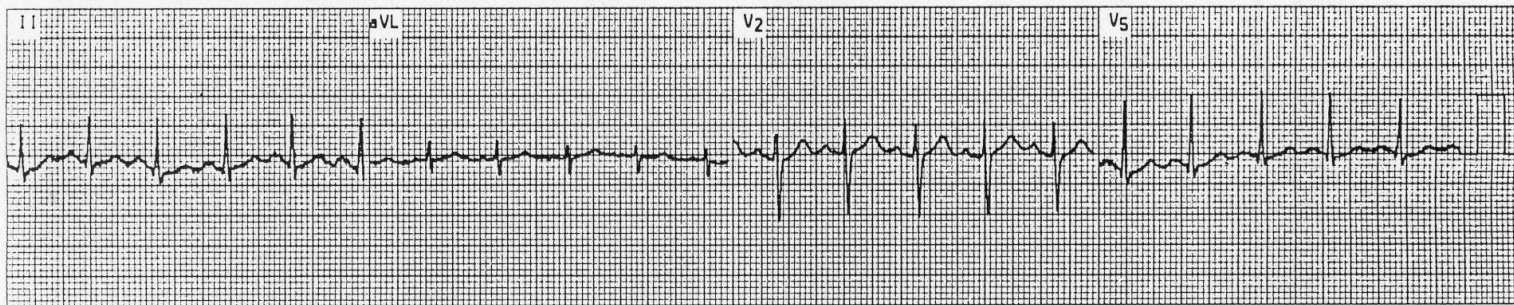
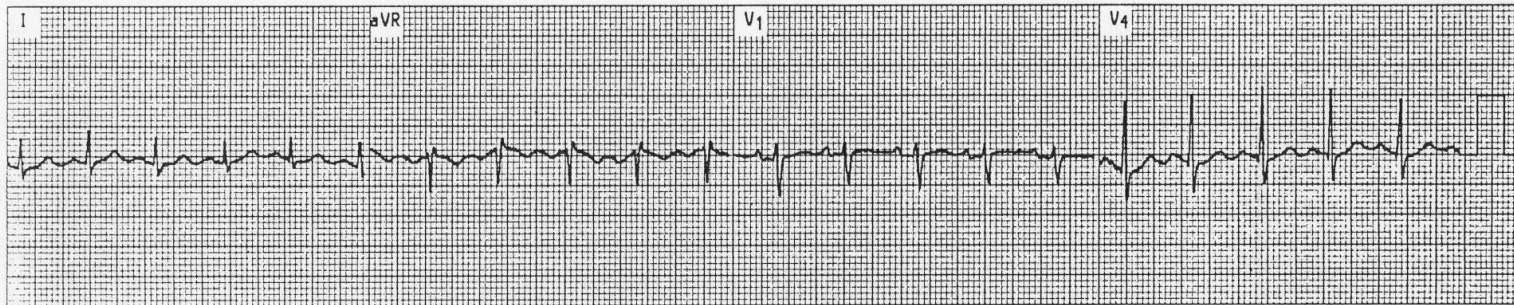
12 Lead ST Level +0.1 Gain x1
 Resting ST Slope +33 HR 76 25 mm/sec



35.

ECG: Stage 1 (Bruce Protocol)
BP: 140/90

12 Lead ST Level +0.0 Gain x1
Stage 1 2:50 ST Slope +6 HR 122 25 mm/sec



36.

ECG: Max exercise

BP: 158/90

Comments : Note continuing ST-segment depression. It has progressed to 3-4mm and is totally downsloping in V₃, V₄, and V₅.

12 Lead

ST Level -2.5

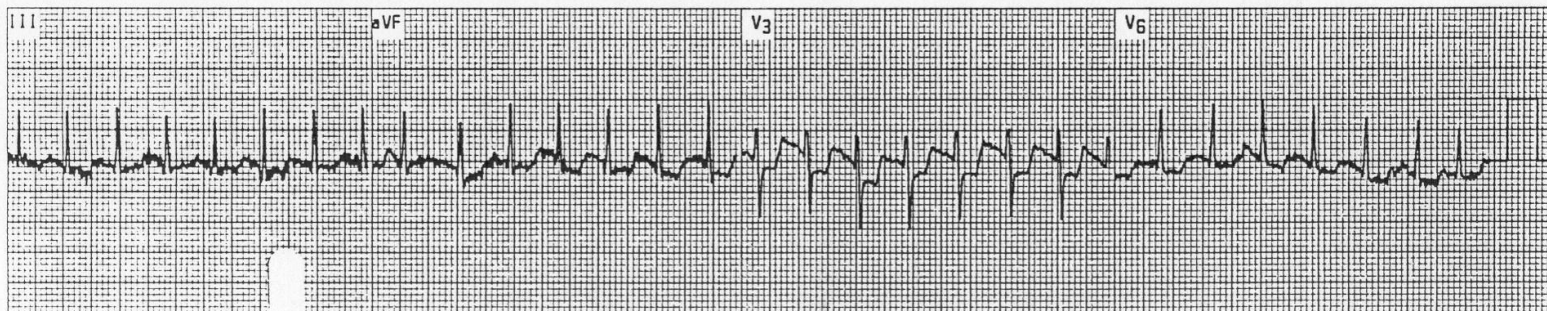
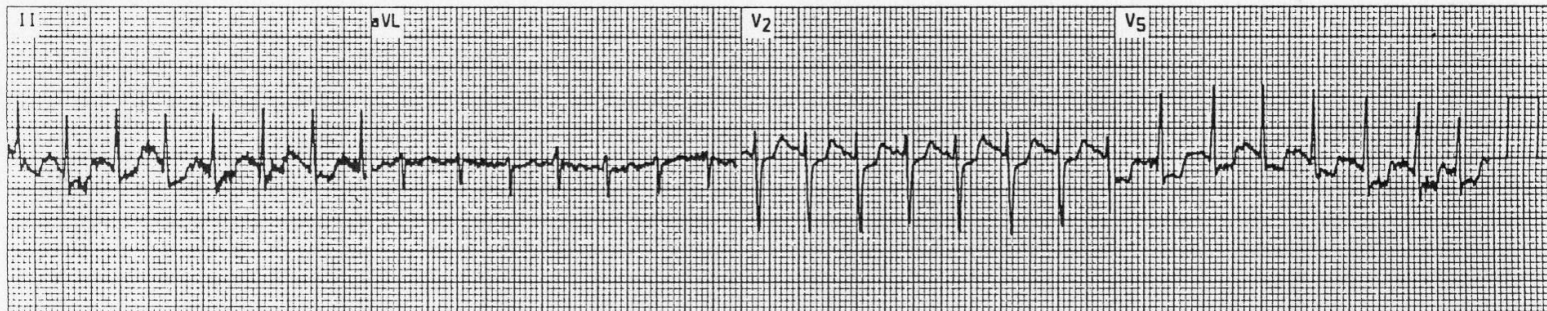
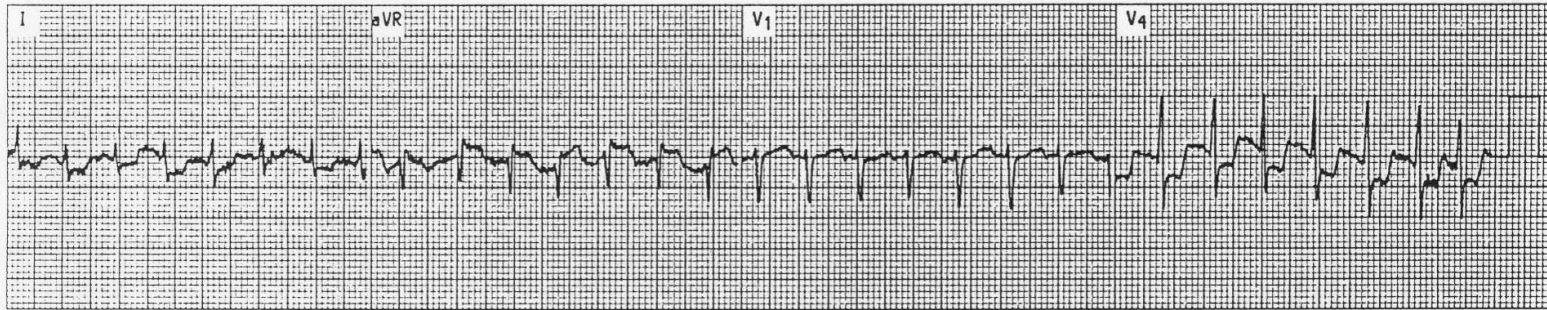
Gain x1

Recovery 0:00

ST Slope +0

HR 170

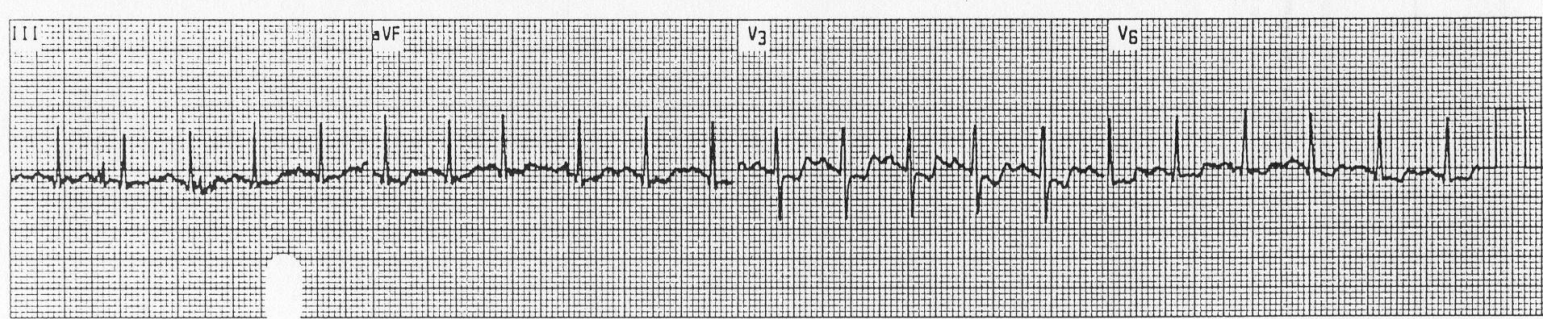
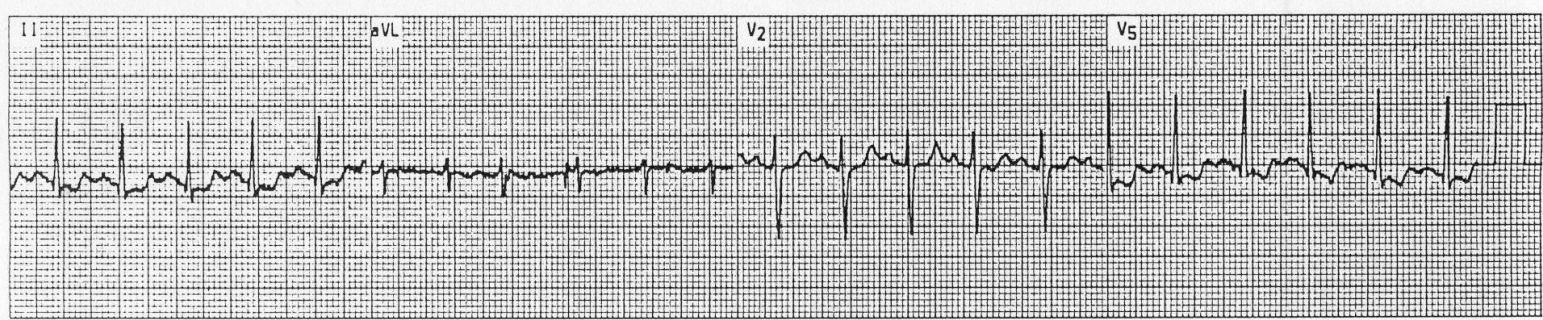
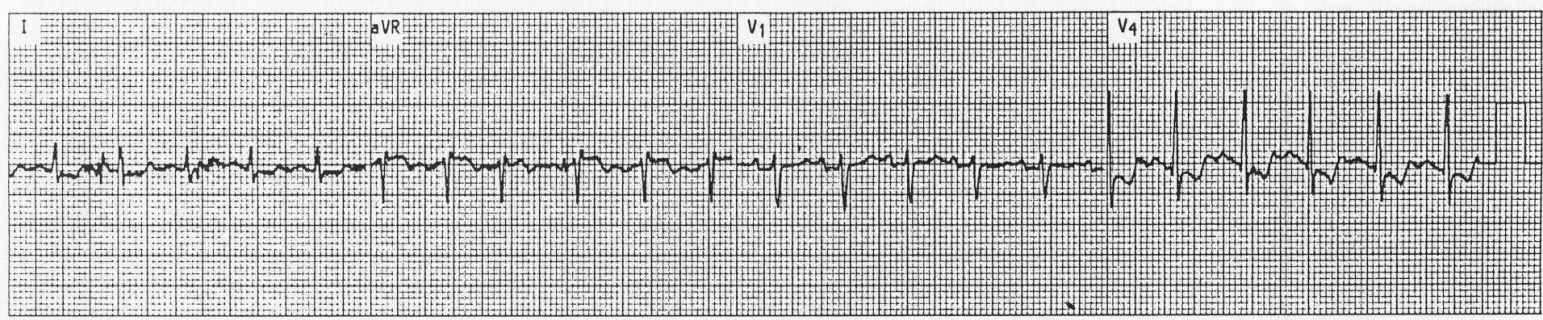
25 mm/sec



37.

12 Lead ST Level -1.5 Gain x1
Recovery 4:00 ST Slope -5 HR 129 25 mm/sec

ECG: 4-minute recovery
BP: 136/90
Comments : ST-segment depression persists into recovery, lending strength to the premise that the test is true positive. Follow up angiography demonstrated significant blockages in three coronary arteries.



Key to ECG Tracings & Diagnostic Imaging

1. Depiction of 3 dimensional cardiac vector (left axis deviation)
2. Normal with Rhythm Strip (J.S. Green, Summer 1989)
3. Sinus Arrhythmia
4. Atrial Fibrillation
5. Atrial Flutter
6. PVC's comprising 40% of complexes
7. Premature Atrial Contraction
8. Premature Junctional (Nodal) Contraction
9. Ventricular Tachycardia
10. Ventricular Fibrillation (Continuation of tracing #8)
11. Wolf Parkinson White
12. Wolf Parkinson White
13. 2nd degree AV Block Mobitz I (Wenckebach)
14. 2nd degree AV Block Mobitz I (Wenckebach)
15. 2nd degree AV Block Mobitz II
16. 3rd degree AB Block (Complete Heart Block)
17. Pacemaker Rhythm (Note "spikes" in front of ventricular QRS complexes)
18. Right Bundle Branch Block
19. Right Bundle Branch Block
20. Right Bundle Branch Block
21. Left Bundle Branch Block
22. Left Anterior Hemiblock
23. Left Posterior Hemiblock with Tachycardia
24. Right Atrial Hypertrophy, old inferior MI, posterior directed cardiac vector
25. Left Ventricular Hypertrophy
26. Left Ventricular Hypertrophy
27. Non-specific T and ST changes (ST "scooping" – possible sign of ischemia)
28. Old Inferiolateral MI
29. Acute Inferior MI
30. Normal Thallium
31. Abnormal Thallium
32. Abnormal Cardiac Catheterization
33. Cardiac Catheterization of same patient as in plate #32 after angioplasty
34. - 37. Case study ECG's with narrative